

## Multidetector-row CT imaging of the liver : Is a high concentration of contrast material effective ?

Kazuhiro SAITO, Jinho PARK, Shuming XU, Ryota NISHIO,  
Yoko SHIMAZAKI, Dai KAKIZAKI

Department of Radiology, Tokyo Medical University

---

### Abstract

*Purpose* : The purpose of this study was to evaluate the effect of the concentration of contrast material to obtain good quality arterial phase images with a multi-detector CT.

*Materials and method* : We divided 77 patients into the following 2 groups : the moderate concentration group (300 mgI/mL, maximum dose 150 mL, 37 cases), and the high concentration group (370 mgI/mL, maximum dose 100 mL, 40 cases). The contrast material dose was adjusted by the patient's body weight (600 mgI/kg) and administration was followed by saline flush. The injection duration was fixed (30 seconds). A monitoring scan was used with the trigger threshold set at 200 HU. Quantitative evaluation of the aorta, liver parenchyma and tumor-liver contrast between moderate and high concentration contrast material was performed. We qualitatively evaluated the conspicuity of the hepatic artery, portal vein, hepatic vein and tumor.

*Results* : There was no significant difference in the time to reach the trigger threshold and the beginning of the arterial phase scan. Quantitative and qualitative evaluation of the aorta, hepatic parenchyma and tumor-liver contrast also revealed no significant difference. Interobserver agreement was good for the qualitative evaluation of the conspicuity of the hepatic artery, portal vein and hepatic vein.

*Conclusion* : Similar arterial phase images could be obtained by both moderate and high concentration of contrast material.

---

### Introduction

Multi detector-row CT (MDCT) enable a reduction of acquisition time for the whole liver and improved spatial resolution of the z axis compared with single slice helical CT. Recently the number of detectors has been increased, so MDCT has 40 to 64 detectors and the acquisition time is less than before. Because of the remarkably shortened acquisition time with recent MDCT, previous acceptable injection parameters for acquisition timing<sup>1)</sup> may not be suitable for detection of hypervascular liver tumors. The time of aortic peak enhancement could be estimated when the contrast

medium was adjusted for the weight of the patient and the injection duration of contrast material was fixed<sup>2)</sup>. Therefore the optimal scan starting time for hypervascular tumors could be determined<sup>3)</sup>. Bolus tracking is indispensable to acquire the optimal timing with MDCT with many detectors. It has been reported that the scan should start at a definite period from the trigger point<sup>1)</sup>.

The contrast material injection protocol is a significant factor for the detection of hypervascular tumors, especially hepatocellular carcinoma (HCC). In particular, the total amount of iodine and the amount of iodine injected per second were significant<sup>4-6)</sup>. Even if the total amount of iodine injected were the same, a

---

Received October 18, 2008, Accepted February 25, 2008

**Key words** : Multidetector-row CT, Liver, Contrast medium, Hepatocellular carcinoma

**Corresponding author** : Department of Radiology, Tokyo Medical University, 6-7-1 Nishishinjuku, Shinjuku-ku, Tokyo 160-0023, Japan

TEL : 03-3342-6111 (ext. 5818), FAX : 03-3348-6314

difference in the amount of iodine injected per second affects tumor detection<sup>5)</sup>. That means that the high or moderate concentrations of a contrast material could affect the tumor detection. Awai et al. reported the tumor-liver contrast was higher in the group using a moderate concentration of contrast medium than with a higher concentration<sup>7)</sup>. We therefore sought to determine whether high concentration or moderate concentration contrast media would be suitable for the detection of hypervascular tumor with MDCT using 64 detectors.

**Materials and methods**

**Subjects**

The subjects consisted of 100 consecutive patients scheduled for abdominal CT examination. They were classified into the following two groups: high concentration (Iopamiron 370 mgI/mL, Schering, Osaka), moderate concentration (Omnipaque 300 mgI/mL, Daiichi-Sankyo Pharmaceutical, Tokyo). Both contrast materials were in pre-filled syringes and the amounts of high and moderate concentration contrast material were 100 mL and 150 mL, respectively. Namely, the total amounts of iodine in the high and moderate contrast material concentration were 37 g and 45 g, respectively. We used a high concentration in the first period of the study and moderate concentration in the second period. Exclusion criteria were: extravasation of contrast material at injection site, occurrence of adverse reactions, impossibility of breath holding, metal artifacts, huge liver tumors, obstruction of the main or first branches of the right or left portal vein. The remaining subjects consisted of 40 patients in the high concentration group and 37 patients in the moderate concentration group. Forty-three patients had chronic liver disease and 15 patients had HCC. There was no significant difference between the two groups in age, weight (one-way analysis of variance), gender ( $\chi^2$  test), the numbers of patients with chronic liver disease and HCC, and the size of HCC (one-way analysis of variance). The details of each group shown in Table 1. All chronic liver diseases arose from type C viral hepatitis. The diagnosis of HCC was obtained from angiography-assisted CT (10 patients), biopsy under ultrasound guidance (4 patients) and operation (1 patient). When there were many HCC nodules in a patient, the 3 largest nodules were chosen.

This study followed the Helsinki Declaration and written informed consent was obtained.

**CT acquisition**

All patients were scanned with a 64-detector scanner (Sensation Cardiac 64, Siemens, Erlangen, Germany). Five-phase contrast-enhanced CT scannings of the liver was performed during plain, early arterial, late arterial, portal and equilibrium phases. Acquisition parameters were as follows: rotation time, 0.5 second; beam collimation, 32×0.6 mm; reconstruction slice thickness, 5 mm; helical pitch, 0.9.

A bolus tracking program was used to time the start of early arterial phase scanning after contrast material injection. The CT number was monitored at the L1 vertebral body level and the region of interest (ROI) cursor was placed in the abdominal aorta. Real time, low-dose (120 kVp, 20 mAs) serial monitoring scan every 1.49 second began 10 seconds after the start of contrast material injection. The trigger threshold was set at an increase of 200 Hounsfield units (H.U.) over the aortic baseline CT number. Early arterial phase scanning was started at 7 seconds after the trigger threshold. Late arterial phase scanning started 4 seconds after the end of the early arterial phase. Portal phase and equilibrium phase scanning started 70 and 180 seconds after the beginning of injection of contrast material, respectively.

**Contrast material injection**

The volume of contrast material was adjusted by body weight. Because Yamashita et al. reported that 600 mg of iodine per kilogram of body weight is necessary to achieve sufficient enhancement in chronic liver disease patients<sup>4)</sup>, this is the dose we delivered. The maximum doses of high concentration and moderate contrast material were 100 mL and 150 mL respectively, thus patients weighing more than 75 kg in the moderate concentration group and 61.7 kg in the high concentration group lacked the contrast material. There were 21 patients with insufficient iodine load in the high concentration group and 5 in the moderate concentration group (Table 1). The aortic peak time was the time of injection plus the time to arrive at the aorta<sup>2)8)</sup>. Fixed injection duration makes it easy to estimate the timing of tumor stain in hypervascular tumor because of the fixed timing of aortic peak enhancement<sup>1)3)</sup>. Injection duration was fixed at 30 seconds<sup>3)</sup>. Contrast material was

**Table 1** Demographic data of patients

|         | No. of patients | Age  | Body weight (kg) | Injection rate (mL/s) | Lack of contrast media (patients) | No. of male/female patients | No. of patients with chronic liver disease | No. of patients with HCCs (nodules) | Size of HCC nodules (mm) |
|---------|-----------------|------|------------------|-----------------------|-----------------------------------|-----------------------------|--|-------------------------------------|--------------------------|
| 370 mgI | 40              | 61.2 | 59.1±11.3        | 2.9±0.4               | 21                                | 25/15                       | 21   | 7 (13)                              | 12                       |
| 300 mgI | 37              | 64.3 | 57.5±11.7        | 3.7±0.6               | 5                                 | 22/15                       | 22   | 8 (17)                              | 18                       |

delivered via a 21-gauge intravenous catheter inserted into an antecubital vein with a power injector (Dual Shot, Nemoto Kyorindo, Tokyo, Japan) and followed by flushing with 45 mL saline solution at the same injection rate of the contrast material.

**Time analysis**

The time required to reach the trigger threshold and the time of start in the early arterial and late arterial phases were recorded. The significance of the difference between the high concentration group and the moderate concentration group regarding the mean time required to reach the trigger threshold, the mean time to start the early arterial phase, and late arterial phase were evaluated by Student's *t*-test. *P* values of less than 0.05 were considered to indicate statistically significant differences.

**Quantitative analysis**

One researcher measured the mean attenuation values of the abdominal aorta and hepatic parenchyma with a circular ROI. Aortic attenuation was measured at the level of the celiac trunk. Hepatic attenuation was measured in the left lobe and right lobe at the level of the celiac trunk, and attenuation values for each region were averaged. Contrast enhancement index in the abdominal aorta and liver parenchyma were calculated as the absolute difference in H.U. between the plain CT image and enhanced image. The significance of differences between high concentration and moderate concentration groups in these contrast enhancement indices were evaluated by Student's *t*-test. *P* values of less than .05 were considered to indicate statistically significant differences. Differences between the groups with sufficient and insufficient amounts of iodine were also evaluated.

**Qualitative evaluation**

To evaluate the optimal timing for the early and late arterial phases, two radiologists who had 17 and 15 years of experience performed visual assessment of the conspicuity of the hepatic artery (right hepatic artery), portal vein (from the main portal vein to the bifurcation) and hepatic vein (junction of the inferior vena cava) independently. A 4-point scale was applied as follows: 1, no enhancement; 2, poor enhancement; 3, moderate enhancement; 4, good enhancement. The interobserver variability was evaluated by kappa statistical analysis. A kappa value of 0.4 or less was regarded as slight agreement, 0.41 to 0.60 as moderate, 0.61 to 0.80 as substantial, and 0.81 or more as almost perfect.

The conspicuity of 30 HCC nodules were also evaluated by the same two radiologists and the tumor conspicuity was classified into the following 3 grades: 1, poor conspicuity; 2, fair conspicuity; 3, excellent conspicuity. The significance of differences between the two groups regarding tumor conspicuity was evaluated by Student's *t*-test. The interobserver variability was

evaluated with kappa statistical analysis.

**Results**

**Time evaluation**

Two patients in the high concentration group and 4 in the moderate concentration group did not reach the trigger threshold. The mean time required to reach trigger threshold was  $28.4 \pm 4.3$  seconds in the high concentration group and  $27.1 \pm 4.4$  seconds in the moderate concentration group ( $p=0.16$ ). The starting time of the early arterial phase is  $36.0 \pm 4.6$  seconds after the beginning of contrast material injection in the high concentration group and  $34.5 \pm 4.4$  seconds in the moderate concentration group. The starting time of late arterial phase was  $45.2 \pm 4.3$  and  $44.4 \pm 4.4$  seconds in the high and moderate concentration groups, respectively.

**Quantitative evaluation**

*Abdominal aorta*

The abdominal aorta index values in the moderate group were  $262.7 \pm 47.3$ ,  $275.3 \pm 66.7$ ,  $115.7 \pm 18.2$  and  $71.6 \pm 10.9$  in the early, late arterial phase, portal phase and equilibrium phase, respectively. Those in the high concentration group were  $262.3 \pm 49.8$ ,  $254.0 \pm 77.5$ ,  $114.9 \pm 22.2$  and  $70.8 \pm 10.4$ , respectively. There were no significant differences in any phase between the two groups.

The abdominal aorta index values in the groups with sufficient and insufficient iodine are shown in Table 2. There were significant differences in the portal phase and equilibrium phase values within the high concentration group (portal phase:  $p=.02$ , equilibrium phase:  $p<.01$ ). There were also significant differences within the moderate concentration group in the equilibrium phase (moderate concentration versus high concentration sufficiently:  $p=.03$ , moderate concentration versus high concentration insufficiently:  $p<.01$ ).

**Table 2** The abdominal aorta index value in the groups with sufficient or insufficient contrast medium

|                      | Early arterial | Late arterial | Portal | Equilibrium |
|----------------------|----------------|---------------|--------|-------------|
| 370 mgI sufficient   | 270.0          | 257.1         | 123.5* | 77.9***†    |
| 370 mgI insufficient | 255.4          | 237.1         | 107.0* | 64.7**§     |
| 300 mgI sufficient   | 267.5          | 279.4         | 116.6  | 72.2†§      |
| 300 mgI insufficient | 231.6          | 249.5         | 110.4  | 67.5        |

\* Significant difference ( $p=0.02$ )  
 \*\* Significant difference ( $p<0.01$ )  
 § Significant difference ( $p<0.01$ )  
 † Significant difference ( $p=0.03$ )

**Table 3** The liver parenchyma index value in the groups with sufficient and insufficient contrast medium

|                      | Early arterial | Late arterial | Portal | Equilibrium |
|----------------------|----------------|---------------|--------|-------------|
| 370 mgI sufficient   | 12.6           | 24.0          | 51.5   | 33.2        |
| 370 mgI insufficient | 10.8           | 21.4          | 44.6   | 30.8        |
| 300 mgI sufficient   | 10.6           | 22.5          | 51.0   | 31.9        |
| 300 mgI insufficient | 17.1           | 30.7          | 53.6   | 29.9        |

*Liver parenchyma*

The liver parenchyma index values in the group loaded moderate concentration iodine were  $11.5 \pm 9.4$ ,  $23.7 \pm 13.5$ ,  $51.4 \pm 14.9$  and  $31.6 \pm 5.9$  in early, late arterial phase, portal phase and equilibrium phase, respectively. Those in the high concentration group were  $11.6 \pm 9.1$ ,  $22.6 \pm 11.2$ ,  $47.9 \pm 11.9$  and  $31.9 \pm 5.9$ , respectively. There were no significant differences between the high and moderate concentration groups in any phase.

The liver parenchyma index values of the groups with sufficient and insufficient iodine are shown in Table 3. There were no significant differences among any combinations.

*Tumor—liver contrast*

The tumor-liver contrast index values were  $21.9 \pm 11.4$  and  $21.8 \pm 11.0$  in the early arterial phase and  $32.9 \pm 16.2$

and  $30.0 \pm 16.5$  in the late arterial phase in the moderate and high concentration groups, respectively. In the late arterial phase the value was higher than in the early arterial phase in the moderate concentration group but not significantly in the high concentration group (moderate concentration :  $p=0.02$ , high concentration :  $p=0.15$ ).

**Qualitative analysis**

*Conspicuity of vessels*

Vascular conspicuity evaluation was as shown in Tables 4 and 5. Good enhancement of hepatic artery was obtained in both early and late arterial phases in the two groups. Though the enhancement of the portal vein was weak in the early arterial phase, there was moderate enhancement in the late arterial phase. In the hepatic vein, no enhancement or only poor enhancement was obtained (Fig. 1). The kappa values in the early arterial and late arterial phase in the moderate concentration group were 0.75 and 0.77. In the high concentration group they were 0.72 and 0.78, respectively. There was substantial interobserver agreement regarding the conspicuity of vessels.

*Conspicuity of tumor*

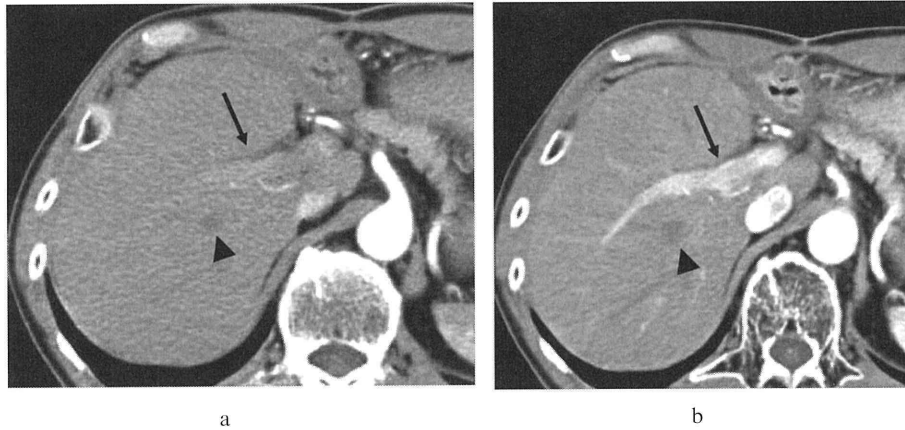
Tumor conspicuity evaluation was as shown in Table 6. Tumor conspicuity was higher in the late than in the early arterial phase according to both observers (Fig. 2). Kappa values were 0.21 and 0.17 in the early arterial phase of the moderate and high concentration group, respectively, so interobserver agreement was slight. In the late arterial phase they were 0.52 and 0.46 in the

**Table 4** Qualitative evaluation of CT imaging with 300 mgI/ml contrast medium

|                      | Observer A     |             |              | Observer B     |             |              |
|----------------------|----------------|-------------|--------------|----------------|-------------|--------------|
|                      | Hepatic artery | Portal vein | Hepatic vein | Hepatic artery | Portal vein | Hepatic vein |
| Early arterial phase | 3.9            | 2.4         | 1.0          | 4.0            | 2.3         | 1.1          |
| Late arterial phase  | 3.9            | 3.1         | 1.3          | 3.9            | 3.0         | 1.4          |

**Table 5** Qualitative evaluation of CT imaging with 370 mgI/ml contrast medium

|                      | Observer A     |             |              | Observer B     |             |              |
|----------------------|----------------|-------------|--------------|----------------|-------------|--------------|
|                      | Hepatic artery | Portal vein | Hepatic vein | Hepatic artery | Portal vein | Hepatic vein |
| Early arterial phase | 3.9            | 2.4         | 1.2          | 3.8            | 2.1         | 1.2          |
| Late arterial phase  | 3.9            | 3.2         | 1.3          | 3.8            | 3.0         | 1.4          |



**Fig. 1** a. early arterial phase  
b. late arterial phase

The hepatic artery is markedly enhanced in both early arterial and late arterial phase. The portal vein is poorly enhanced in the early arterial phase, but moderately enhanced in the late arterial phase (arrow). The hepatic vein has no enhancement in either the early arterial or the late arterial phase (arrowhead).

**Table 6** Tumor conspicuity

|            | Observer A     |               | Observer B     |               |
|------------|----------------|---------------|----------------|---------------|
|            | Early arterial | Late arterial | Early arterial | Late arterial |
| 300 mgI/mL | 2.1            | 2.4           | 2.2            | 2.6           |
| 370 mgI/mL | 2.2            | 2.5           | 2.2            | 2.5           |

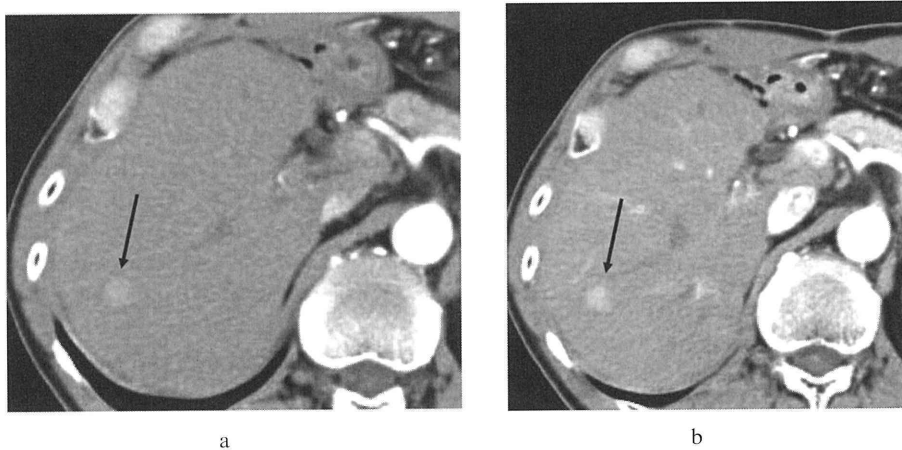
moderate and high concentration groups, indicating moderate agreement.

**Discussion**

Some cases did not reach the trigger threshold of 200 H.U. over baseline, therefore it was not possible to obtain scanning with optimal timing in those cases. Before performing this study, we thought it would be

better to scan after obtaining sufficient aortic peak enhancement to shorten the delay time, because of the shortened scan time enable by the 64 detectors CT. However, it was thought necessary to set the lowest trigger threshold at 200 H.U. over the aortic baseline value from this study. A previous report using a 40-detector MDCT set the trigger threshold of 100 H.U.<sup>1)</sup> and the delay time had to be set longer than in the present study. As a result, due to the increased delay time reliability factor decreases when setting a low trigger threshold lower. In future, we needed to determine the aortic peak accurately.

In this study, the density of the aorta and liver parenchyma in the early and late arterial phases did not significantly differ in the two groups with moderate and high concentrations. High concentration contrast medium is usually between 350 mgI/mL and 400 mgI/mL, and moderate concentration is between 240



**Fig. 2** a. early arterial phase  
b. late arterial phase

The conspicuity of the tumor is better in the late arterial phase than in the early arterial phase. Arrow indicates hepatocellular carcinoma.

mgI/mL and 300 mgI/mL. We adjusted the amount of contrast material according to the patient's body weight and used a fixed injection time. When the amount of iodine per time was fixed, there was no significant difference in aortic enhancement between with the moderate and high concentration groups<sup>2)</sup>. The aortic enhancement in the moderate group was higher than that of the high concentration group in both the early and late arterial phases, but there was no statistically significant difference. Awai et al. reported similar results<sup>7)</sup>. They postulated that without use of a saline flush, a significant amount of contrast is temporarily trapped in the dead space of the peripheral vein, detracting from the amount of iodine visualized. There is still a trend, but apparently not statistically significant in this study using a 45-mL saline flush, suggesting that this hypothesis at least partially accounts for the findings. The injection rate and the viscosity of the contrast medium might also affect the findings.

Hepatic enhancement depended on the total amount of iodine<sup>9)</sup>. In this study we adjusted the amount of contrast material according to the body weight, so significant difference in hepatic enhancement was not seen between the moderate and high concentration groups.

Tumor-liver contrast did not significantly differ between the moderate and high concentration groups. Naturally, in the moderate concentration group, the overall amount of contrast medium that needed to be delivered was greater than the volume of higher concentration contrast medium, and that in turn necessitated a more rapid injection rate in order to deliver the same amount of iodine within the fixed-time 30-second injection. Ichikawa et al.<sup>10)</sup> reported that faster injection increased false positive results, for example arterioportal shunt, when the 350 mgI/mL contrast material was injected at 3 mL and 5 mL per second. In the present study, because the maximum dose of contrast material was 150 mL, the maximum injection rate was 5 mL per second in the fixed 30-second injection. There was therefore some possibility of inducing false positive results. Although there were no false positive results in this study, this point requires attention.

It was reported that the late arterial phase is useful to detect hypervascular tumors<sup>11)12)</sup>. Foley et al. reported the optimal late arterial phase, i.e. the portal venous inflow phase, was suitable for detection of HCC. In this phase, the hepatic artery is predominantly enhanced and the portal vein is also moderately enhanced but the hepatic vein was not enhanced. The late arterial phase was confirmed to correspond to the portal inflow phase in this qualitative study and it was thought to yield imaging with optimal timing. The conspicuity of tumor was confirmed to be clearer in the late arterial

phase than in the early arterial phase. The timing of scanning was not significantly different using moderate or high concentrations of contrast material. Moreover the tumor conspicuity was also not significantly different, probably because we adjusted the amount of contrast material according to the patient's body weight and used a fixed injection time, namely the amount of iodine per fixed injection time was fixed.

In conclusion both moderate and high iodine concentrations of contrast material obtained equal enhancement effect in the arterial phase, when trigger thresholds were at 200 H.U. over baseline with a 64-detector MDCT and contrast material was given according to the patient's body weight and injected in 30 seconds.

### References

- 1) Sultana S, Awai K, Nakayama Y, Nakaura T, Liu D, Hatemura M, Funama Y, Morishita S, Yamashita Y : Hypervascular hepatocellular carcinomas : Bolus tracking with a 40-detector CT scanner to time arterial phase imaging. *Radiology* **243** : 140-147, 2007
- 2) Awai K, Hiraishi K, Hori S : Effect of contrast material injection duration and rate on aortic peak time and peak enhancement at dynamic CT involving injection protocol with dose tailored to patient weight. *Radiology* **230** : 142-150, 2004
- 3) Kanematsu M, Goshima S, Kondo H, Niahibori H, Kato H, Yokoyama R, Miyoshi T, Hoshi H, Onozuka M, Moriyama N : Optimizing scan delays of fixed duration contrast injection in contrast-enhanced biphasic multidetector-row CT for the liver and the detection of hypervascular hepatocellular carcinoma. *J Comput Assist Tomogr* **29** : 195-201, 2005
- 4) Yamashita Y, Komohara Y, Takahashi M, Uchida M, Hayabuchi M, Shimizu T, Narabayashi I : Abdominal helical CT : evaluation of optimal doses of intravenous contrast material-a prospective randomized study. *Radiology* **216** : 718-723, 2000
- 5) Awai K, Takada K, Onishi H, Hori S : Aortic and hepatic enhancement and tumor-to-liver contrast : analysis of the effect of different concentrations of contrast material at multi-detector row helical CT. *Radiology* **224** : 757-763, 2002
- 6) Furuta A, Ito K, Fujita T, Koike S, Shimizu A, Matsunaga N : Hepatic enhancement in multiphasic contrast-enhanced MDCT : Comparison of high- and low-iodine-concentration contrast medium in same patients with chronic liver disease. *AJR* **183** : 157-162, 2004
- 7) Awai K, Inoue M, Yagyu Y, Watanabe M, Sano T, Nin S, Koike R, Nishimura Y, Yamashita Y : Moderate versus high concentration of contrast material for aortic and hepatic enhancement and tumor-to-liver contrast at multi-detector row CT.

- Radiology **233** : 682-688, 2004
- 8) Bae KT, Heiken JP, Brink JA : Aortic and hepatic peak enhancement at CT : Effect of contrast medium injection rate-pharmacokinetic analysis and experimental porcine model. Radiology **206** : 455-464, 1998
- 9) Hanninen EL, Vogl TJ, Felfe R, Pegios W, Balzer J, Clauss W, Felix R : Detection of focal liver lesions at biphasic spiral CT : Randomized double-blind study of the effect of iodine concentration in contrast materials. Radiology **216** : 403-409, 2000
- 10) Ichikawa T, Nakajima H, Nanbu A, Hori M, Araki T : Effect of injection rate of contrast material on CT of hepatocellular carcinoma. AJR **186** : 1413-1418, 2006
- 11) Francis IR, Cohan RH, McNulty NJ, Platt JF, Korobkin M, Gebremariam A, Ragupathi KI : Multidetector CT of the liver and hepatic neoplasms : Effect of multiphasic imaging on tumor conspicuity and vascular enhancement. AJR **180** : 1217-1224, 2003
- 12) Foley WD, Mallisee TA, Hohenwarter MD, Wilson CR, Quiroz FA, Taylor AJ : Multiphase hepatic CT with a multirow detector CT scanner. AJR **175** : 679-685, 2000

## 肝臓のマルチディテクター CT : 高濃度造影剤は有効か？

齋藤和博      朴辰浩      徐樹明  
西尾龍太      嶋崎洋子      柿崎大

東京医科大学放射線医学講座

目的：マルチディテクター CT を用いた肝臓ダイナミック CT の動脈相の画質に対する造影剤濃度の影響を検討する。  
対象及び方法：77 患者を以下の 2 グループにわけた。中濃度造影剤群：300 mgI/mL、最大容量 150 mL、37 例、高濃度群：370 mgI/mL、最大容量 100 mL、40 例。投与造影剤量は 600 mgI/kg であり、患者毎に調整し、生理食塩水で後押しを施行した。注入時間は 30 秒間であり固定とした。モニタースキャンを使用し、腹部大動脈のトリガーを 200 HU とした。大動脈、肝実質、腫瘍-肝コントラストに関して中濃度造影剤群と高濃度造影剤群で定量的評価を行った。また、肝動脈、門脈、肝静脈の明瞭度に関して定性的評価を行った。

結果：中濃度造影剤、高濃度造影剤群間でトリガー到達時間、動脈相開始時間に有意差は認められなかった。定量的評価に関しては、大動脈、肝実質、腫瘍-肝コントラストに中濃度、高濃度群間に有意差は認められなかった。肝動脈、門脈、肝静脈の明瞭度に関しての観察者間の一致度は良好であった。

結語：中濃度、高濃度造影剤ともに同様な動脈相の画像が得られる。

---

<キーワード> マルチディテクター CT、造影剤、肝細胞癌

---