

## Improvement of the soft-cup aspirator in laparoscopic surgery of ovarian cysts and evaluation based on experiments and clinical experiences

Akiko NAKAJIMA, Keiichi ISAKA, Toshitaka OGAWA, Masaomi TAKAYAMA

Department of Obstetrics and Gynecology, Tokyo Medical University

---

### Abstract

The most challenging problem in laparoscopic surgery for ovarian tumors is how to make the tumor smaller and resect it while preventing the intraperitoneal leakage of the fluid content. We devised a puncture aspirator and evaluated its performance both experimentally and clinically. We carried out our experiments using the fluid content obtained from ovarian cysts and evaluated the effectiveness of two types of the soft-cup aspirators in 222 cases of laparoscopic surgery for benign ovarian cysts. It was possible to lift up a cyst weighing approximately 190 g with a cup 10 mm in diameter and cyst weighting 300 g with a cup 12 mm in diameter by applying a suction pressure of  $-250$  mmHg. When the fluid content was drawn out by suction at  $-100$  mmHg, no difference was observed in the suction rate at a higher viscosity among the puncture needles of different size whereas when out by suction of  $-650$  mmHg, a larger puncture needle was capable of suction even with a higher viscosity and a higher suction rate. Clinically, no leakage was observed in 87% of cases of serous cyst adenomas when a 10 mm outer barrel and the 11 G puncture needle were used. No leakage was observed in 74% of the cases of mature teratoma when a 12 mm outer barrel and the 7 G puncture needle were used, respectively. Leakage was observed in 55% and 56% of the cases of endometrial cysts when the 10 mm outer barrel and the 12 mm outer barrel were used respectively. From our experiments and clinical experiences, we have confirmed that the two types of soft-cup aspirators, used selectively depending on the diseases concerned, can make ovarian cysts smaller safely.

---

### Introduction

We started laparoscopic surgery under pneumoperitoneum in 1992. Then we adopted a gasless hanger lifting method using two steel wires in 1993 in order to reduce the incidence of complications associated with pneumoperitoneum. We also adopted another hanger lifting method using one steel wire in the midline below the umbilicus in 1994.<sup>1)2)</sup> Since these methods proved to have more merits than laparotomy or laparoscopic surgery using pneumoperitoneum, the laparoscopic surgical operations for benign ovarian diseases was increased from 49% in 1992 to 85% in 1998 at our hospital, and now they have been established as surgical standards

for benign ovarian diseases. Leakage of the fluid content in respecting a malignant ovarian tumor is known be closely related to prognosis.<sup>4)–9)</sup> Therefore, in order to prevent the defluxion and leakage of the fluid content at the suction-puncture site when making a tumor smaller by drawing out the fluid content by suction in cystectomy through an abdominal port, we developed a soft-cup aspirator in 1995. Since then we have been using a soft-cup aspirator in performing surgery for ovarian cysts.<sup>13)</sup> Though we could generally perform puncture and suction without any leakage of the fluid content in the cases of ovarian cysts, we sometimes found it difficult to perform the procedure in cases of mature teratoma and endometrial cysts due to components and

---

Received October 29, 2002, Accepted January 16, 2003

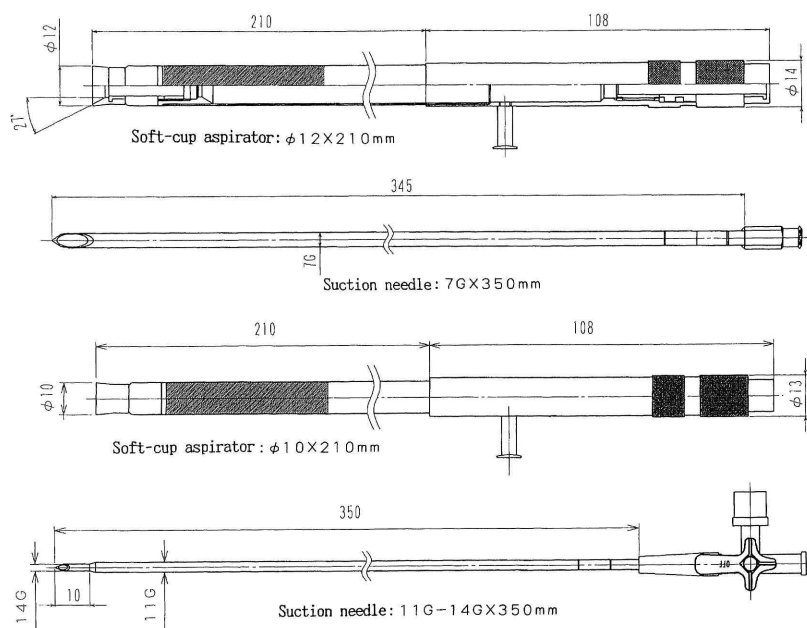
**Key words** : Gasless laparoscopy, Laparoscopic surgery, Laparoscopic cystectomy of an ovarian tumor, Soft-cup aspirator

**Reprint requests** to : Akiko NAKAJIMA, Department of Obstetrics and Gynecology, Tokyo Medical University, 6-7-1 Nishishinjyuku Shinjyuku-ku, Tokyo160-0023, Japan


viscosity of the fluid content. To solve the problem, we made further improvements in the original soft-cup aspirator for better performance and evaluated the effectiveness of the original soft-cup aspirator and the

improved soft-cup aspirator in a series of experiments. This paper reports the results of our evaluation.

**a**



**b**



**Fig. 1 a.b.** Two kinds of soft-cup aspirators

a. The two aspirators

b. 1. Top: 10 mm OD Bottom: 12 mm OD

2. Top: 10 mm OD Bottom: 11 G puncture needle

3. Tips are made of silicone

4. Top: 12 mm OD Bottom: 7 G puncture needle

2	1
3	4

## Materials and Methods

### 1. Materials

We carried out our experiments using the fluid content obtained from three cases of ovarian serous cysts, two cases of mature teratoma and three cases of endometrial cysts. In addition, we evaluated the effectiveness of the original soft-cup aspirator and the improved soft-cup aspirator used in 222 cases of laparoscopic surgery for benign ovarian cysts performed in our Department from 1996 through 1998.

### 2. Methods

The soft-cup aspirator consists of an outer barrel and an inner-barrel puncture needle. The outer barrel made of stainless steel has a suction port, at which suction pressure is applied to attach resilient silicone tip by suction to the surface of the cyst. Then, the inner-barrel puncture needle made of stainless steel, is inserted in to the cyst to aspirate out the fluid content by suction (Fig. 1). We used both the original soft-cup aspirator consisting of an outer barrel 10 mm in outside diameter (OD) and a 14 G or 11 G inner-barrel puncture needle and the improved soft-cup aspirator consisting of an outer barrel 12 mm in OD and a 7 G inner-barrel puncture needle. The outer barrel was placed and attached by suction in such a way that the soft-cup aspirator would be perpendicular to the surface of the cyst. Then, the cyst was punctured and the fluid content was aspirated (Fig. 2). We studied (1) the relation between viscosity and temperature in the three kinds of fluid content obtained from three cases of ovarian serous cysts, two cases of mature teratoma and three cases of endometrial cysts, using viscosimeter (RM180 Rhemetric Scientific co.), (2) the relation between the suction pressure of the outer barrel and attaching force by suction, using vacuum aspirator system (VP400 ATM med.co.) and (3) the relation between the suction pres-

sure of the inner barrel, the suction rate and viscosity when the outer barrel was attached by suction with the suction pressure held constant. In the experiment we were using a fluid content having a similar viscosity.

In clinical evaluation, transvaginal ultrasound and serum tumor markers were used in all cases for differential diagnosis of benign and malignant ovarian diseases. CT and/or MRI were also used for differential diagnosis. Laparoscopic surgery was not indicated for cases in which the possibility of malignancy could not be denied. The cases of benign ovarian cysts in which laparoscopic surgery was performed were classified into two groups evaluation, those in which any leakage was observed while using the original or the improved soft-cup aspirator and those in which no leakage was observed macroscopically.

## Results

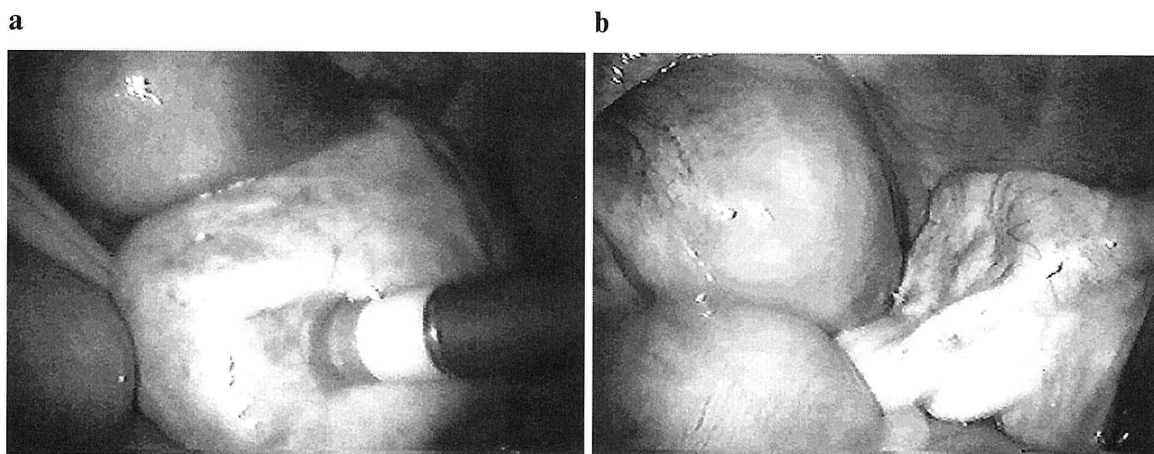
### 1. Experimental evaluation

#### (1) The relation between viscosity and temperature studied on the fluid content.

The fluid content of ovarian serous cysts had a viscosity of approximately 1–10 mill Pascal second (mPa.s). They were minimally viscous, and the viscosity was little affected by temperature. The fluid content of teratoma had a high viscosity of 200–1,000 mPa.s at normal body temperature. However, they solidified at lower temperatures. The fluid content of endometrial cysts had a wide range of viscosity of 6–1,000 mPa.s. The viscosity increased to some degree at lower temperatures (Fig. 3).

#### (2) The relation between the suction pressure of the outer barrel and the suction attachment force.

The suction attachment force by increased in proportion to the suction pressure in the outer barrel attached to the cyst. It was possible to lift up a cyst of approximately 190 g with the 10 mm outer barrel and a cyst of approximately 300 g with the 12 mm outer barrel by



**Fig. 2 a.b.** How to use the soft-cup aspirator  
 a. The soft-cup aspirator is attached perpendicularly to the cyst by suction  
 b. The needle is inserted and the content is aspirated

applying a suction pressure of  $-250$  mmHg, which is normally used in our operation room (Fig. 4).

**(3) The relation between the suction pressure of the inner barrel, the suction rate and viscosity when the outer barrel was attached by constant suction.**

After the outer barrel was attached by suction with its suction pressure held constant at  $-250$  mmHg, the target was punctured with inner-barrel puncture needles of different sizes and the fluid content was drawn out by suction with a 50 ml syringe. For this purpose, the suction pressure of the inner barrel to which little suction force was applied was set at  $-100$  mmHg whereas the suction pressure of the inner barrel to which strong force was applied was set at  $-650$  mmHg. The viscosity of the experimental content fluid was increased from 1 mPa.s through 10 mPa.s and 100 mPa.s to 1,000 mPa.s and the suction rate (ml/min) was set at  $-100$  mmHg (Fig. 5) or  $-650$  mmHg (Fig. 6), for the 14 G, 11 G and

7 G puncture needles. When the fluid content was drawn out by suction at  $-100$  mmHg, no difference was observed in the suction rate for fluid with a higher viscosity among the puncture needles of different sizes, whereas when the content fluid was drawn out by suction at  $-650$  mmHg, a larger puncture needle was capable of suction even with higher viscosity fluid and had a higher suction rate. At a viscosity of 1 mPa.s, even the 14 G puncture needle attached to a 50 ml syringe could draw out the content fluid by suction at approximately 100 ml/min whereas, at a viscosity of 1,000 mPa.s, the 7 G puncture needle could draw out the content fluid by suction at approximately 25 ml/min with strong force (Fig. 7).

**(4) Clinical evaluation**

The soft-cup aspirator was clinically used to make cysts smaller in 222 cases of laparoscopic surgery : 96 cases (43%) of mature teratomas, 93 cases (42%) of

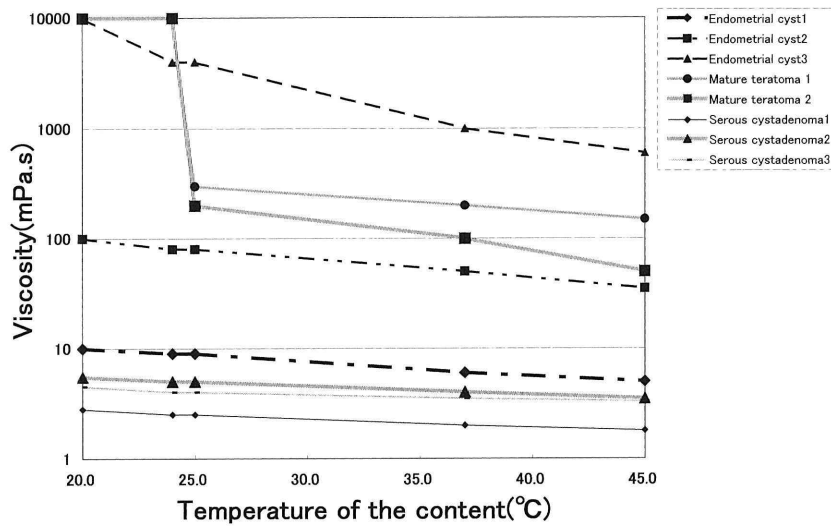


Fig. 3 Relationship between temperature of the content fluid and viscosity

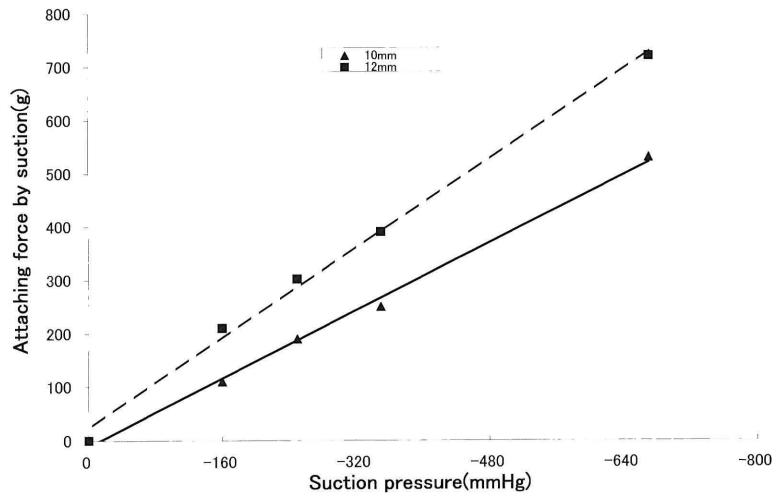


Fig. 4 Relationship between suction force of the outer barrel and attaching force by suction

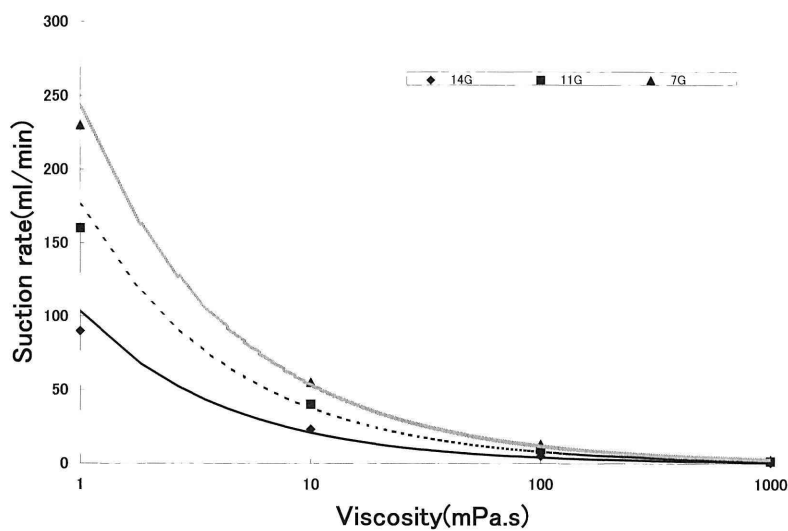


Fig. 5 Relationship between suction rate and viscosity (−100 mmHg)

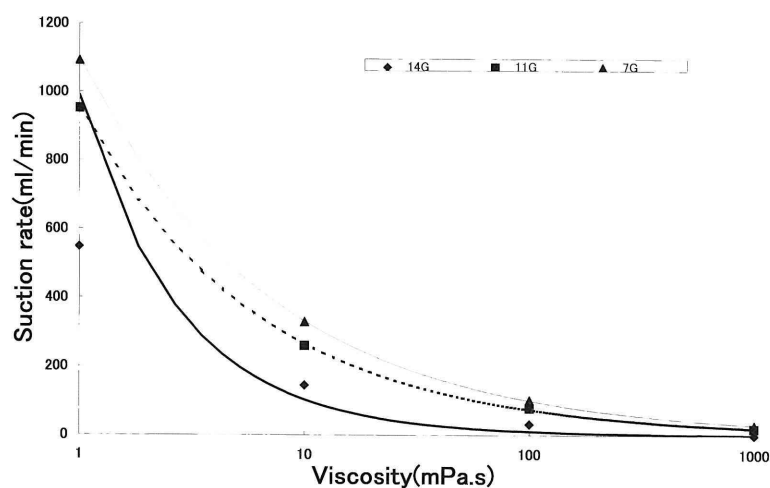


Fig. 6 Relationship between suction rate and viscosity (−650 mmHg)

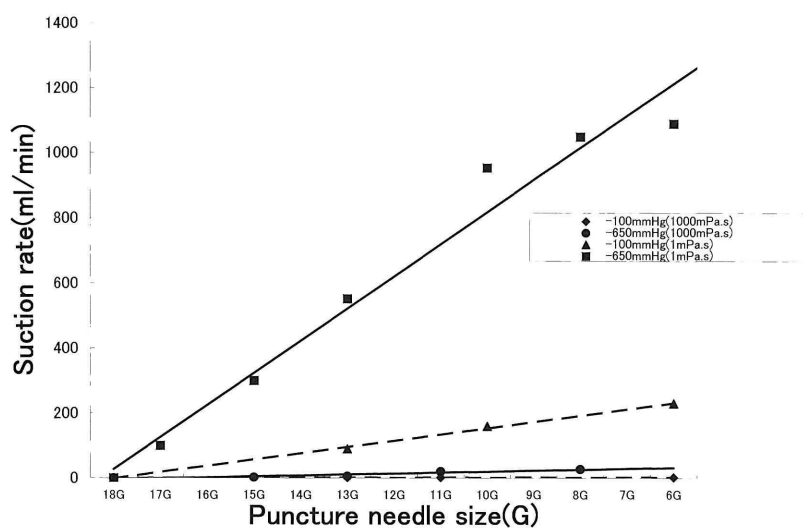


Fig. 7 Relationship between suction force and puncture needle size (viscosity=1 mPa.s and 1,000 mPa.s, suction pressure=−100 mmHg and −650 mmHg)

Table 1

	Mature teratoma		Serous cystadenoma		Endometrial cyst		Mucous cystadenoma	
	10 mm	12 mm	10 mm	12 mm	10 mm	12 mm	10 mm	12 mm
Macroscopic leakage (+)	(45%)	(26%)	(12%)		(55%)	(56%)	(13%)	
	42	14	22	0	38	4	7	0
Macroscopic leakage (—)	(55%)	(74%)	(88%)		(45%)	(44%)	(87%)	
Total	77	19	25	0	84	9	8	0

endometrial cysts, 25 cases (11%) of serous cystadenomas and 8 cases (4%) of mucous cystadenomas. In mature teratomas, macroscopic leakage was observed in 45% of the cases when the 10 mm outer barrel and the 11 G puncture needle were used whereas the incidence of leakage was reduced to 26% when the 12 mm outer barrel and the 7 G puncture needle came into use. The leakage from the puncture site to its surroundings is sucked up or wiped off with a gauze before it flows into the abdominal cavity, and the puncture site is ligatured with suture thread after the removal of the puncture needle. As for serous cystadenomas, leakage was observed in only 12% of the cases when the 10 mm outer barrel and the 11 G puncture needle were used. There has been no case in which the 12 mm OD outer barrel and the 7G puncture needles were used. Leakage was not due to a rupture at the time of puncture but due to the sliding of the outer barrel attached by suction or minimal leakage around the puncture pore after the removal of the puncture needle. In endometrial cysts leakage was observed in 55% of the cases when the 10 mm outer barrel and the 11 G puncture needle were used, whereas it was observed in 56% of cases when the 12 mm outer barrel and the 7 G puncture needle were used, thus there was no difference. In the cases of endometrial cysts, rupture occurred with considerable frequency during surgery due to adhesion after puncture. As for mucous cystadenomas, there was no case in which the 12 mm outer barrel and the 7 G puncture needle were used. Leakage was observed in 13% of the cases when the 10 mm outer barrel and the 11 G puncture needle were used (Table 1).

### Discussion

Laparoscopic surgery is indicated for benign ovarian cyst. In recent years the number of patients who prefer to have laparoscopic surgery has increased because of its low invasiveness. However, since laparoscopic surgery requires that a cyst will be made smaller for cystectomy, there is the possibility that an ovarian cancer, misdiagnosed as a benign tumor might be advanced from stage 1a to stage 1c(b). It is a matter of discussing whether advancing the stage from 1a to 1c(b) has any effect on prognosis or not. According to Sasaki et al.<sup>3)4)</sup>

Kodama et al.<sup>5)6)</sup>, Vergote I et al.<sup>7)</sup> and Konno et al.<sup>8)</sup>, it has no effect on of five years survival. Shioda et al.<sup>9)</sup> reported, however, that significant difference was observed in the five years survival rate. Whichever the case may be, what is essential is to take great care in making a preoperative diagnosis as to the applicability of laparoscopic surgery to an ovarian cyst and to minimize the risk of cancer cell implant due to surgical operations. Suzuki et al.<sup>10)</sup> reported the usefulness of preoperative diagnostic imaging. We ourselves use ultrasonic tomography as a basic technique in preoperative diagnosis, and CT, MRI and other diagnostic imaging as well as CA-125, CA19-9 and other tumor markers in diagnosis. Nevertheless, it is reported that even when a diagnosis is made with utmost care, up to 0.9% of the cases preoperatively diagnosed as a benign tumor actually turn out to be malignant. According to Mage et al.<sup>11)</sup>, 0.86% of the cases diagnosed as a benign tumor on ultrasonic tomography and operated on laparoscopically turned out to be malignant ovarian tumors, while Nezhat et al.<sup>12)</sup> reported the rate to be 0.4%. It is therefore necessary to take into consideration the possibility that a case diagnosed as a benign ovarian tumor may be actually malignant. Therefore, surgery needs to be performed without any leakage of the content fluid even when a case has been diagnosed preoperatively as a benign tumor. Even in the case of a benign tumor, the leakage of the fluid content due to a failure of surgical operations may cause various postoperative complications, including pyrexia resulting from extensive intraperitoneal infection, adhesion and the exacerbation of lesion. Therefore, the leakage of the content fluid should be avoided whenever possible.

A variety of aspirators of the fluid content of the ovary have been developed, such as the Topper endoscopic cyst aspirator and the SAND balloon catheter by Ikuma et al.<sup>13)</sup> although the scientific analysis of its efficacy was unclear. The soft-cup aspirator<sup>14)</sup> we devised has a tip at the suction end of the outer barrel shaped like a woven hat. The resilient silicone tip suitable for continuous suction and easy attachment minimizes both the leakage at the puncture site associated with the insertion of the puncture needle and the sliding of the puncture needle. Of the several trial



silicone tips with different angles, the present model has proved to be the most suitable for attachment by suction. Our experiments showed that a soft-cup aspirator with this tip could lift up an object weighing 190 g at a suction pressure of  $-250$  mmHg if the 10 mm outer barrel is used or an object weighing 300 g when the 12 mm outer barrel is used.

As for mature teratomas, the viscosity of the fluid content has been found to be 200–1,000 mPa.s. In the experiment using a content fluid having a similar viscosity (1,000 mPa.s), the soft-cup aspirator with the 11 G puncture needle failed to provide effective suction even when force was applied, and it took a long time to make the tumor smaller. On the other hand, the soft-cup aspirator with the 7G puncture needle managed to provide some suction when force was applied, and it took only a short time to make the tumor smaller. One problem is that the fluid content solidifies at around  $25^{\circ}\text{C}$ . Because temperature in pelvic is about  $36^{\circ}\text{C}$  but when we aspirate the fluid content at operation, temperature of it is as same as temperature in the room. Thus, if the soft-cup aspirator with the 11 G puncture needle is used in the clinical settings it takes such a long time to make a tumor smaller that the liquid fat component will solidify inside the needle or the extension tube during suction due to the change in temperature, making suction difficult. It is therefore advisable to use the 7 G puncture needle in order to make the tumor smaller in a short time before the liquid fat component begins to solidify. A mature teratoma contains not only fat component but also teeth, hair, cartilage and other solid components. Hair in particular tends to occlude the puncture needle. Since mature teratoma is found most frequently among younger women who may wish to give birth to a child, cystectomy with the conservation of the ovary is the standard procedure. At the same time, it is important not to break the cyst in order to prevent postoperative complications. As for mature teratomas, as was reported by Sekimoto et al.<sup>15)</sup> and Suzuki et al. 16), they may have developed into a malignant type on rare occasions. There are also cases of immature teratomas. It is therefore important to decide on the type of surgery not only on the basics of results of diagnostic imaging but also on the patient's age and the results of preoperative examination using scc or other tumor markers. Taking these things into consideration, we perform intracorporal cystectomy only when we judge that a cyst diagnosed as neither malignant nor immature can be enucleated easily, so that we may avoid an intraperitoneal rupture of the cyst. We usually use the soft-cup aspirator with the 7 G puncture needle to make the cyst smaller by aspirating as much content as possible in a short time. Then, we grasp the puncture site with a pair of forceps for ligation. After pulling a

portion of ligature thread out of the body through the abdominal port, we enlarge the rate of aspiration at the puncture site and use a larger suction tube to draw out the content further by suction. We also use a pair of forceps to take out hair and solid tissues little by little so that we can make the cyst smaller and then take it out of the body. As Table 1 shows, though leakage occurred rather frequently when the 11 G puncture needle was used for aspirating the content, it is substantially possible to avoid leakage when the 7 G puncture needle is used.

As for serous cystadenomas, which are not affected by changes in temperature because the viscosity of the content fluid has been found to be as low as 1–10 mPa.s, an experiment was carried out by setting the viscosity of the content fluid at 1 m Pa.s. We attached the outer barrel by suction and used the 11 G puncture needle for puncture and suction. Even when only  $-100$  mm Hg was applied for suction with little force, a suction rate of approximately 150 ml/min was achieved and the cyst was made smaller in a short time. In clinical applications, leakage was not observed in 22 of the 25 cases of serous cystadenomas. In the three cases in which leakage was observed macroscopically, it could have been avoided with sufficient care because it resulted from an improper attachment site or puncture site, an improper attachment angle or premature lifting and sliding off of the device during suction. Even a fairly large serous cystadenoma can be made smaller in a short time. This technique will prove of particular advantage in elderly people because laparoscopic surgery can be completed quickly. We performed laparoscopic surgery using the soft-cup aspirator on an 80 year-old woman with a unilocular serous cystadenoma 20 cm in diameter. The technique enabled her to leave her bed and be discharged early.

As for endometrial cysts, the viscosity of the content fluid varies greatly in because it can be as thin as blood or as thick as mud. Depending on the viscosity, it can be drawn out with ease using the 11 G puncture needle or only with difficulty even using the 7 G puncture needle. In cases of endometrial cysts, adhesion to surroundings can frequently occur, so that it is often difficult to take out the cyst without any rupture of the cyst or any leakage of the content fluid. What is more important, endometrioid carcinomas, clear cell adenocarcinomas, serous adenocarcinomas and other types of adenocarcinomas have been observed to coexist with endometrial cysts.<sup>17)</sup> Careful preoperative examination is required in deciding the method of laparoscopic surgery for endometrial cysts, which are often detected in younger patients who want to give birth to a child. We usually perform cystectomy unless the cyst is found to be malignant on cytological diagnosis of the fluid content or frozen section diagnosis. In doing this,

we think it possible to enhance the effectiveness of suction by aspirating the content fluid with the soft-cup aspirator and then infusing a normal saline solution to irrigate the inside of the cyst so that the remaining content fluid may be diluted.

As for mucous cystadenomas, the viscosity of the content fluid was not determined in our study. The content fluid is clinically known to be as viscous as jelly so that it is difficult to draw it out by suction.

Mucous cystadenomas are multilocular in most cases, and frequently malignant or borderline. For these reasons we use the soft-cup aspirator only for young women with an obviously benign unilocular cyst who want to give birth to a child.

### Conclusion

From our experiments and clinical experiences we have confirmed that the two kinds of soft-cup aspirators, used selectively depending on the diseases concerned, can make ovarian cysts smaller safely. Though laparoscopic surgery has come to be performed for a wider range of diseases with its development, the nature of the procedure requires careful consideration in applying it to ovarian cysts. In addition to the preoperative screening of malignant cases, the prevention of intraoperative leakage is also of utmost importance. The soft-cup aspirator seems to provide excellent result.

### Acknowledgements

We express our thanks to Hakko Shoji Co., Ltd. for their great cooperation in the development and improvement of the soft-cup aspirator.

### References

- 1) Nakajima A, Isaka K, Ogawa T, Kosugi Y, Koshiishi M, Takada J, Takayama M: Gynecological laparoscopic surgery using a hanger lifting method. *Acta Obstetrica et Gynaecologica Japonica* **46**: 919-920, 1994
- 2) Isaka K, Nakajima A, Hosaka M, Kosugi Y, Ogawa T, Takayama M: Operativeness and economy of a hanger lifting method (TMC method) applied in the midline below the umbilicus. *Obstetrical and Gynecological Practice* **44**: 735-740, 1995
- 3) Sasaki H: Treatment of an ovarian tumor in laparoscopic surgery. *Japanese Journal of Gynecologic and Obstetric Endoscopy* **10**: 37-41, 1994
- 4) Sasaki H: Prognosis of the defluxion of the content fluid of an ovarian tumor. *Obstetrical and Gynecological Practice* **44**: 741-746, 1995
- 5) Kodama S, Tanaka K, Tokugawa A, Sudo N, Takahashi T, Matsui K: Multivariate analysis of prognostic factors in patients with ovarian cancer stage I and II. *Int Clin Oncol* **56**: 147-153, 1997
- 6) Kodama S, Kase H, Tanaka K, Tokugawa A, Sudo N, Takahashi T, Honma S: Multivariate analysis of prognostic factors in stage I ovarian cancer. *Int Clin Oncol* **4**: 91-95, 1999
- 7) Vergote I, De Brabanter J, Fyles A, Bertelsen K, Einhorn N, Sevelde P, Gore ME, Kaern J, Verrelst H, Sjøvall K, Timmerman D, Vandewalle J, Van Gramberen M, Trope CG: Prognostic importance of degree of differentiation and cyst rupture in stage I invasive epithelial ovarian carcinoma. *Lancet*. **20**: 176-179, 2001
- 8) Konno R, Shimizu T, Murakami S, Sato S, Yajima S: Problems of endoscopic surgery for an ovarian tumor (specifically its relation with a malignant tumor). *Japan Society of Gynecologic and Obstetric Endoscopy*: **15**: 29-33, 1999
- 9) Shioda M, Takashima T, Ogawa S, Shina M, Ikeda M, Hoshiai S: Indication of laparoscopy - including the possibility of an early malignant tumor. *Advances in Obstetrics and Gynecology* **49**: 30-34, 1997
- 10) Suzuki M, Kurabayashi K, Yasuda M: Clinical evaluation of preoperative diagnostic imaging for laparoscopic surgery for an ovarian tumor. *Obstet Gynecol. (Tokyo)* **7**: 1021-1025, 1995
- 11) Mage G, Canis M, Manhes H, Pouly J, Wattiez A, Bruhat MA: Laparoscopic management of adnexal cystic masses. *J Gynecol Surg* **6**: 71-79, 1990
- 12) Nezhat F, Nezhat C, Welandar C, Beningo B: Four ovarian cancers diagnosed during laparoscopic management of 1011 women with adnexal masses. *Am J Obstet Gynecol* **167**: 790-796, 1992
- 13) Ikuma K, Koyasu Y, Yamada Y, Wakimoto E: Laparoscopic surgery for an ovarian cyst - a method using the SAND balloon catheter. *Rinsho Fujinka Sanka (Clinical Gynecology and Obstetrics)* **51**: 473-475, 1997
- 14) Isaka K, Ogawa T, Hosaka M, Nakajima A, Kosugi Y, Takayama M: Experience of the usefulness of the new puncture aspirator called the soft-cup aspirator in laparoscopic surgery for an ovarian tumor. *Acta Obstetrica et Gynaecologica Japonica* **48**: 307-310, 1996
- 15) Sekimoto R, Jobo T, Iwatani H, Kuramoto H, Nishijima M: Examination of seven cases of mature teratoid cysts with epidermoid carcinomas. *Acta Obstetrica et Gynaecologica Japonica Kanagawa* **33**: 67-71, 1997
- 16) Suzuki Y, Yodate T, Funayama H, Suzuki Y, Isaka K, Nagata J, Okabe K, Takayama M: Three cases of dermoid cysts which turned malignant. *Obstet Gynecol (Tokyo)* **59**: 301-306, 1992
- 17) Kohama M, Fujishita A, Nakamura K, Fukuda M, Miyamura T, Zosaki H, Nakajima H, Ishimaru T: One case of an ovarian serous adenocarcinoma coexistent with a chocolate cyst of ovary. *Japanese Journal of Gynecologic and Obstetric Endoscopy* **14**: 63-69, 1998



## 卵巣腫瘍の腹腔鏡下手術におけるソフトカップアスピレーターの有効性：ソフトカップアスピレーターの改良とその実験的考察 および使用経験について

中 嶋 章 子      井 坂 恵 一      小 川 俊 隆  
高 山 雅 臣

東京医科大学産科婦人科学講座

【要旨】 術前検査で悪性腫瘍をすべて選別除外する事の難しい卵巣腫瘍の腹腔鏡下手術において最大の問題点はいかに内容液の腹腔内露出を防ぎながら腫瘍を縮小し切除できるかということである。この対策として我々は穿刺吸引器ソフトカップアスピレーターを2種類考案し実験的および臨床使用の検討を加えた。実験的検討には実際の卵巣腫瘍の内容液を使用した。また東京医科大学病院産科婦人科学教室で卵巣良性腫瘍で腹腔鏡下手術を施行しソフトカップアスピレーターを使用した222症例について臨床的にその有効性を検討した。実験的検討では外筒10 mm 針11Gのソフトカップアスピレーターは190 gの腫瘍を、外筒12 mm 針7Gでは300 gの腫瘍をそれぞれ吸引圧 $-250$  mmHgで持ち上げることが出来た。また $-100$  mmHgで内容液を吸引した場合穿刺針が太くても粘調度が高くなければその吸引量は差はないが $-650$  mmHgで吸引した場合は穿刺針が太ければ粘調度が高くても吸引が可能で吸引量も増加した。実際に手術時の使用経験では漿液性嚢胞腺種は外筒10 mm 針11Gで87%が漏出なく、成熟奇形腫では外筒12 mm 針7Gで74%が漏出しなかった。子宮内膜症では外筒10 mm、12 mmとも55%、56%と同等であった。今回の実験的見地と実際の使用経験から2種類のソフトカップアスピレーターを疾患により選択し使用することでより安全に卵巣腫瘍の縮小をはかることが出来ることが示唆された。

---

〈Key words〉 ガスレス ラパロスコピー、腹腔鏡下手術、腹腔鏡下卵巣腫瘍摘出術、ソフトカップアスピレーター

---