

症 例 報 告

## Anesthetic management of prone-position surgery in a morbidly obese patient

Takao MUTO, Hiroyuki UCHINO, Toshiaki TAKAHASHI, Takeshi SAGARA,  
Yutaka SOGABE, Toshie SHIRAIISHI, Go HIRABAYASHI, Hideto KANEKO,  
Akibumi OMI and Nagao ISHII

Department of Anesthesiology, Tokyo Medical University Hachioji Medical Center

### Abstract

We reported the anesthetic management of a morbidly obese patient with a body mass index (BMI) of 49. Morbidly obese patients often present with variety of pathological conditions in circulatory, respiratory, and endocrine systems. Obesity itself, its complications, and its treatment have significance for the anesthesiologist. We successfully performed anesthesia for a laminectomy in the prone position in this obese patient. Surface anesthesia and superior laryngeal blocks were performed with a lidocaine, followed by awake intubation. Then, the patient moved himself to the operating table and assumed a prone position. During the anesthesia, respiration was controlled by monitoring the physiological dead space ( $V_D$ ) and the ratio of physiological dead space to tidal volume ( $V_D/V_T$ ) using a Ventrak 1550. Except for a minor occurrence of increased blood  $\text{CO}_2$  concentration and decreased oxygen partial pressure and oxygen saturation, the surgery was completed smoothly, without any postoperative complications.

### Introduction

The anesthetic management of a morbidly obese patient is often associated with complications. Respiratory complications such as hypoxia and hypercapnea and airway obstruction frequently occur in obese patients, with a higher risk during changes in body position. This report describes the safe anesthetic management of prone-position laminectomy in a morbidly obese patient and smoothly completed surgeries without any postoperative complications.

### Case report

The patient was a 29-year-old man with morbid obesity, with a body mass index (BMI) of 49, height 165 cm and body weight 135 kg. Numbness started in both legs around 1998, with difficulty in walking beginning in

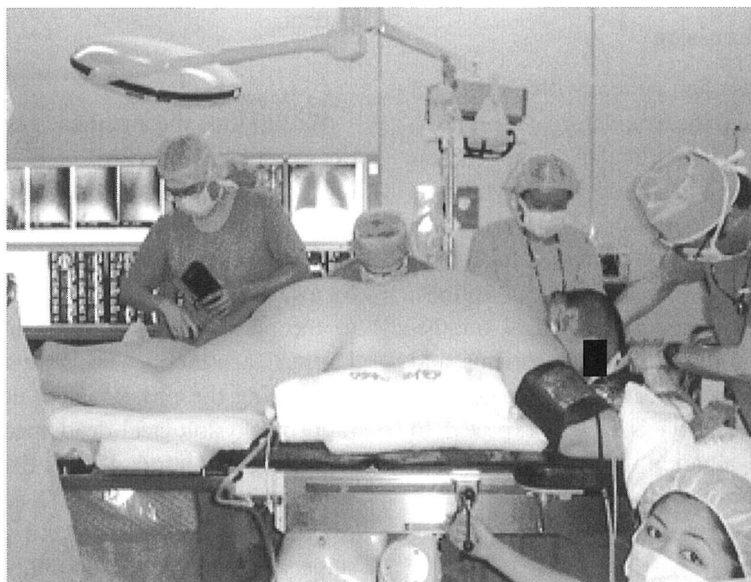
October 2001. Lumbar ossification of the posterior longitudinal ligament was diagnosed and a laminectomy scheduled. The patient showed mild hypercapnia on blood gas analysis with normal respiratory function. The patient's anatomical characteristics were 6 cm between the thyroid cartilage and chin, 8 cm lower jaw, a maximal mouth opening of two fingerbreadths, difficulty in neck extension, pushing out of the lower jaw and a thick broad neck. The Mallampati class was four.

In the operating room, without premedication, bilateral superior laryngeal nerve block was performed with an injection of 1% lidocaine. Then, tracheal intubation was performed orally with the patient still conscious, using a bronchofiberscope. The patient moved to the operating table and changed his body to the prone position by himself. While confirming that the patient

Received January 29, 2004, Accepted March 15, 2004

**Key words:** Anesthetic management, Prone-position surgery, Morbid obesity

**Correspondence to:** Dr. Takao Muto, Department of Anesthesiology, Tokyo Medical University Hachioji Medical Center, 1163 Tate-machi, Hachioji-city, Tokyo 193-0998, Japan



**Fig. 1** Self-positioning into an optimal prone position by patient himself  
In this picture, the physician is confirming the optimal body position with the patient before propofol administration.

**Table 1** Blood gas parameters, dead space volume, and ratio of dead space to tidal volume

	F <sub>I</sub> O <sub>2</sub>	pH	PaCO <sub>2</sub> (mmHg)	PaO <sub>2</sub> (mmHg)	SaO <sub>2</sub> (%)	V <sub>T</sub> (ml)	V <sub>D</sub> (ml)	V <sub>D</sub> /V <sub>T</sub>	PEEP (cmH <sub>2</sub> O)
Before induction	1.0	7.36	55	258	100	475	204	0.43	0
After 60 min in prone position	0.5	7.44	55	71	95	698	377	0.54	0
After PEEP	0.5	7.34	36	128	99	649	245	0.38	5
Postoperative supine position	0.5	7.46	45	110	99	647	233	0.36	5

V<sub>D</sub>/V<sub>T</sub> was 0.43 under spontaneous respiration, and increased to 0.54 after 60 minutes (with ventilation) in the prone position. However, it decreased to 0.38 and the gas composition improved 30 minutes after changing the setting of tidal volume increasing to 900 ml, and adding 5 cmH<sub>2</sub>O PEEP.

had no pain in his abdomen and four limbs, the optimum position was obtained (Figure 1). The general anesthesia was induced by intravenous administration of 200  $\mu$ g fentanyl, 110 mg propofol and 10 mg vecuronium. During the surgery, administration of propofol was continued to achieve a calculated blood concentration of 1–3  $\mu$ g/ml using the target-control infusion (TCI) system. Fentanyl, 50 to 100  $\mu$ g, was administered every hour, to maintain anesthesia. A bispectral index (BIS) monitor was used for determining anesthetic depth. During general anesthesia, the BIS value ranged from 40 to 60, and we were able to get enough depth of anesthesia. The mechanical ventilation was performed by tidal volume of 700 ml, respiratory rate of 15 ventilations per minute, with 0 cm H<sub>2</sub>O positive end-expiratory pressure (PEEP), and 50% inspiratory oxygen concentration (2 L/min oxygen and 4 L/min air). An increase in blood CO<sub>2</sub> concentration and decreases in oxygen partial pressure and oxygen saturation were observed after about 60 minutes in the prone position. There-

fore, ventilation was increased to 900 ml, and 5 cmH<sub>2</sub>O PEEP was added, resulting in an improvement 30 minutes later. In addition, respiration was controlled by monitoring the physiological dead space (V<sub>D</sub>) and the ratio of physiological dead space to tidal volume (V<sub>D</sub>/V<sub>T</sub>) using a Ventrak 1550 (Novamatrix Co.). V<sub>D</sub>/V<sub>T</sub> was 0.43 under spontaneous respiration, and increased to 0.54 after 60 minutes (with ventilation) in the prone position. However, it decreased to 0.38 and the gas composition improved 30 minutes after changing the setting of the ventilator (Table 1). The surgery was completed smoothly without any other significant changes in the circulatory system, and the patient was changed to the supine position, followed by termination of propofol administration. After awakening about 3 minutes later, his trachea was extubated and he was moved to the intensive care unit (ICU). No postoperative complication occurred in the ICU. He returned to the ward on the 1st postoperative day, and was discharged on the 21st postoperative day.

## Discussion

Morbidly obese patients often present with a variety of pathological conditions in the circulatory, respiratory, and endocrine systems<sup>1)</sup>. In particular, complications of hypoventilation syndrome and sleep apnea syndrome (SAS) are often seen<sup>2,3)</sup>. Pathological changes also include decreased lung compliance, decreased functional residual capacity (FRC), and increased closing volume. For these reasons, respiratory control in general anesthesia is often very difficult in morbidly obese patients, and tracheal intubation becomes difficult due to anatomical obstruction<sup>4)</sup>. When intubation is clearly expected to be difficult from the evaluation of Mallampati and mouth-opening, awake intubation using a bronchofiberscope appears to be an effective method for inducing anesthesia smoothly.

For general anesthesia in morbidly obese patients, a large number of staff are needed to change the body position, with associated high risks<sup>5,6)</sup>. In our case, the risk was reduced by letting the patient himself change his body position. Additionally, optimal positioning by the patient himself was very effective for preventing of postoperative pain and nerve injuries from restraining devices. A preoperative explanation of a procedure of awake intubation and self change in prone position was important to introduce anesthesia smoothly for the morbid obese patient. In addition, it was also effective to practice changing position in the preoperative period.

Normally, mechanical ventilation in the prone position is used to improve oxygenation, which is reduced compared to that in the supine position<sup>7,8)</sup>. Better oxygenation is reported to be obtained by not compressing the chest area with restraining devices in morbidly obese patients<sup>9,10)</sup>. In our case, a 4-point spinal frame was used to minimize the respiratory obstruction from pressure on the chest, but deterioration of oxygenation and an increase in the ratio of dead space to tidal volume could not be prevented. As a result, decrease of FRC (functional respiratory capacity) and inefficient ventilation were induced due to restricted thoracic movement by the patient's weight itself.

With a Ventrak 1550, single breath carbon dioxide (SBCO<sub>2</sub>) is calculated by the consecutive measurement of carbon dioxide and ventilation flow using a mainstream-type breath CO<sub>2</sub> sensor. From the SBCO<sub>2</sub> and an arterial blood CO<sub>2</sub> partial pressure by blood gas analysis, the physiologic dead space ( $V_D$ ), ratio of physiological dead space to tidal volume ( $V_D/V_T$ ) and CO<sub>2</sub> output are calculated. This is well recognized as a respiratory and circulatory monitor for the patients under mechanical ventilations<sup>11,12)</sup>. In our case, the Ventrak was very useful to evaluate physiological dead space for respiratory control in the morbidly obese

patient.

## Conclusion

We reported the anesthetic management of a morbidly obese patient with a BMI of 49. We successfully performed anesthesia for laminectomy in the prone position in the obese patient. Surface anesthesia and superior laryngeal blocks were performed with lidocaine, followed by awake intubation. Then, the patient moved himself to the operating table and assumed a prone position. During anesthesia, respiration was controlled by monitoring the physiological dead space ( $V_D$ ) and the ratio of physiological dead space to tidal volume ( $V_D/V_T$ ) using a Ventrak 1550. Except for a minor occurrence of increased blood CO<sub>2</sub> concentration, decreased oxygen partial pressure, and oxygen saturation, the surgery was completed smoothly, without any postoperative complications.

## References

- 1) Kopelman PG : Clinical complications of obesity. Clin Endocrinol Metab **13** : 613-34, 1984
- 2) Koenig SM : Pulmonary complications of obesity. Am J Med Sci **321** : 249-279, 2001
- 3) Wittels EH, Thompson S : Obstructive sleep apnea and obesity. Otolaryngol Clin North Am **23** : 751-60, 1990
- 4) Rocke DA, Murray WB, Rout CC, Gouws E : Relative risk analysis of factors associated with difficult intubation in obstetric anesthesia. Anesthesiology **77** : 67-73, 1992
- 5) Brodsky JB, Oldroyd M, Winfield HN, Kozlowski PM : Morbid obesity and the prone position : a case report. J Clin Anesth **13** : 138-40, 2001
- 6) Wilson AT, Reilly CS : Anaesthesia and the obese patient. Int J Obes Relat Metab Disord **17** : 427-35, 1993
- 7) Rehder K : Postural changes in respiratory function. Acta Anaesthesiol Scand Suppl **113** : 13-6, 1998
- 8) Pelosi P, Croci M, Ravagnan I, Tredici S, Pedoto A, Lissoni A, Gattinoni L : The effects of body mass on lung volumes, respiratory mechanics, and gas exchange during general anesthesia. Anesth Analg **87** : 654-60, 1998
- 9) Palmon SC, Kirsch JR, Depper JA, Toung TJ : The effect of the prone position on pulmonary mechanics is frame-dependent. Anesth Analg **87** : 1175-80, 1998
- 10) Swerdlow BN, Brodsky JB, Butcher MD : Placement of a morbidly obese patient in the prone position. Anesthesiology **68** : 657-8, 1988
- 11) Wenzel U, Wauer RR, Wagner MH, Schmalisch G : *In vitro* and *in vivo* assessment of the Ventrak 1550/Capnogard 1265 for single breath carbon dioxide analysis in neonates. Br J Anaesth **83** : 503-10, 1999

- 12) Hess D, Tabor T: Comparison of six methods to calculate airway resistance during mechanical venti-

lation in adults. J Clin Monit 9: 275-82, 1993

## 高度肥満患者における腹臥位手術の麻酔経験

武 藤 孝 夫	内 野 博 之	高 橋 俊 明
相 良 武 士	曾我部 豊	白 石 としえ
平 林 剛	金 子 英 人	近 江 明 文
	石 井 脩 夫	

東京医科大学八王子医療センター麻酔科

【要旨】 肥満患者の麻酔管理は低酸素血症、高炭酸ガス血症などの呼吸器系合併症や循環動態の変動などが起こりやすく、また体位変換時には危険を伴い注意を要する。今回我々は、高度肥満患者に対して腹臥位による腰椎椎弓切除術の麻酔管理を経験した。症例は29歳男性、身長165 cm、体重135 kg、BMI 49、2001年10月両下肢のしびれおよび歩行困難にて当院整形外科受診し、腰椎後縦靭帯骨化症の診断でL3-5椎弓切除術が予定された。全身麻酔を施行するにあたり本症例は、BMI 49、顎-胸部間6 cmと高度の肥満と猪首を呈しており、また腹臥位手術のため、挿管困難および導入後の体位変換困難が予測された。そのため、意識下挿管したのち自力で至適体位を取ることを決定した。また、術中に呼吸管理モニターである Ventrak を用いて死腔量の変化をモニターし、血液ガス測定と共に呼吸管理の指標とした。入室後、4%リドカインにて咽頭喉頭部を十分に麻酔し両側上喉頭神経ブロックを施行後、意識下に気管支ファイバーを用いて経口的に気管挿管した。次に患者本人により手術台へ腹臥位に体位変換してもらい至適体位を確保した。その後フェンタニル 200  $\mu$ g、プロポフォール 110 mg、ベクロニウム 10 mg にて全身麻酔導入した。術中はプロポフォール予測血中濃度 1-3  $\mu$ g/ml で持続投与した。生理学的死腔 ( $V_D$ ) の変化率は仰臥位の自発呼吸下では 43% であったが、腹臥位では 54% に増加し  $PCO_2$  の上昇や  $PO_2$  の低下がみられたため一回換気量の増加や PEEP 負荷にて対応した。30 分後には  $V_D$  は 38% に低下し血液ガス所見も改善した。その後呼吸循環系に大きな合併症はみられず、無事手術終了し抜管帰室した。以上高度肥満患者の腹臥位麻酔管理を経験し、意識下挿管、患者自身による体位変換、Ventrak による呼吸管理により安全に麻酔管理を施行できた。

---

〈Key words〉 麻酔管理、腹臥位手術、高度肥満

---