

Clinical outcomes of endoscopic treatment in superficial non-ampullary duodenal epithelial tumors

Mami TAKEUCHI¹⁾, Masakatsu FUKUZAWA¹⁾, Takashi KAWAI²⁾, Fuminori MORIYASU¹⁾

¹⁾Department of Gastroenterology and Hepatology, Tokyo Medical University

²⁾Endoscopy Center, Tokyo Medical University Hospital

Abstract

Background & aim : The number of accumulated cases of duodenal adenoma/adenocarcinoma is insufficient to allow the endoscopic characteristics, invasion depth diagnosis, and standard therapeutic method to be established. Here, we report clinicopathological features and endoscopic treatment outcomes in primary non-ampullary duodenal tumor cases at our hospital.

Methods : The clinicopathological features of the patients and tumors, including age, sex, tumor size, location, macroscopic type, and tumor color (red or not) were evaluated with respect to the histopathological diagnosis. The short-term outcomes of each treatment method were compared in terms of rate of complete resection, procedure time, period of hospitalization, and complications. The tumor recurrence rates were compared between 30 lesions in patients followed for 6 months or longer.

Results : On endoscopy, adenocarcinomas were either predominantly red or had patches of red significantly more often than did adenomas ($P < 0.05$). Erosion was seen significantly more frequently with adenocarcinoma than with adenoma ($P < 0.05$). Cancer-bearing rates were examined according to tumor diameter and macroscopic type. No cancer was observed in type 0-IIa or type 0-IIc lesions. The mean tumor diameter in which EMR was performed was 10.9 mm. The mean diameter of the tumors in which EPMR, ESD, HESD, or LECS was performed was ≥ 15 mm. Complete en bloc resection rates were 68.8% for EMR and 100% for HESD, ESD, and LECS.

Conclusion : The cancer-bearing rate of type 0-IIa lesions tended to be low and that of type 0-IIa + IIc or 0-I with a tumor diameter of ≥ 15 mm tended to be high. This indicates that 10-15-mm elevated lesions can be resected completely by EMR. On the other hand, in the case of 10-15-mm recessed lesions suspected as cancer by preoperative endoscopy, ESD or HESD should be considered. Meanwhile, EPMR should be considered for type IIa lesions of ≥ 15 mm, whereas en bloc resection such as HESD, ESD, or surgical resection should be considered for type IIa + IIc lesions. Whether the lesion is cancerous and whether resection can be performed safely should be considered in selecting the therapeutic method.

Introduction

Duodenal adenoma/adenocarcinoma is rare, and its prevalence rate remains to be established. The incidence rate of primary duodenal cancer, however, is reported to be 0.035% for upper gastrointestinal cancer and from 33% to 45% for small intestinal cancer¹⁾.

With recent technological improvements in upper gastrointestinal endoscopy, the number of reported cases of duodenal tumors has gradually increased, and cases of endoscopic resection have been sporadically reported²⁻¹⁸⁾. The number of accumulated cases of duodenal tumors, however, is not as large as that of esophageal, gastric, or colonic cancers. Moreover, the endoscopic charac-

Received September 7, 2015, Accepted December 5, 2015

Key words : Duodenal tumor, Endoscopic resection, Therapeutic outcome

Corresponding author : Mami Takeuchi, 2-25-1 wada, suginamiku, Tokyo 166-0012, Japan

TEL : +81-3-3383-1281 ext.7110 FAX : +81-3-6382-4475

teristics, invasion depth diagnosis, and therapeutic methods for duodenal tumors have not yet been established. Furthermore, endoscopic mucosal resection (EMR)⁵⁻⁷⁾ and endoscopic submucosal dissection (ESD)^{8-11,14)} are associated with an extremely high risk of perforation due to the thinness of the duodenal wall. The duodenum may also be more vulnerable to complications such as delayed bleeding or perforation than other parts of the gastrointestinal tract as it is exposed to bile and pancreatic juice. For these reasons, the duodenum is recognized as the most difficult section of the gastrointestinal tract to treat by endoscopy. This may explain why few studies have reported on the efficacy and safety of endoscopic treatment of duodenal tumors.

Here, we report clinicopathological features and endoscopic treatment outcomes in primary superficial non-ampullary duodenal epithelial tumors at our hospital.

Strategies for endoscopic treatment of duodenal tumors have not yet been established. We believe that the present results will offer useful information in deciding treatment strategies for duodenal tumors.

Material and Methods

This study included 47 duodenal lesions (excluding papillary lesions) in 47 patients who underwent endoscopic treatment for duodenal tumors at Tokyo Medical University between April 2000 and September 2014. The clinicopathological features of the patients and tumors, including age, sex, tumor size, location, macroscopic type, and tumor color (red or not) were investigated in relation to the histopathological diagnosis. Macroscopic duodenal tumors were classified using the criteria for colorectal tumors¹⁹⁾. Short-term outcomes were evaluated in terms of rate of complete resection (CR), procedure time, period of hospitalization, and complications. Bleeding was considered to have occurred if endoscopic hemostatic treatment, such as application of a clip or injection of a hemostatic agent, was required. Tumor recurrence rates between 30 lesions were compared in patients followed for 6 months or longer. The first follow-up gastroscopy was performed 3 or 6 months after the initial resection in patients with tumors showing a histologically positive horizontal margin, and the second follow-up gastroscopy after 1 year. All patients were informed of the risks and benefits of several treatment options, including EMR, ESD, laparoscopic endoscopic collaboration surgery (LECS), and conventional surgery. Informed consent was obtained from all patients, and this research, was carried out in accordance with the Helsinki Declaration as revised in 2000.

Endoscopic procedures

Hot biopsy procedure

This procedure involves using insulating forceps to

collect tissue and destroy residual tumor by heat coagulation, which also serves as the diagnosis and treatment. The polyp is grasped with the forceps and burned out by means of passing a high-frequency current through it. This process can easily be performed in a short time. This approach is best suited to a polyp of less than 5 mm in size.

EMR/EMPR procedures

Both EMR and endoscopic partial mucosal resection (EMPR) were performed by two endoscopists (T.G, M.F). The EMR was performed using a single-channel gastroduodenoscope (GIF Q260 and Q260J, Olympus Medical Systems, Tokyo, Japan). Saline containing a small amount of indigo carmine was used as the injection solution. A spiral snare, SnareMaster (Olympus Medical Systems) or Captivator II Snare (Boston Scientific Co., MA, USA) was used, and was selected in reference to the lesion size or particular situation. Any lesion that could not be resected in its entirety was resected piecemeal. To control or prevent bleeding from visible vessels within the artificial ulcer, bipolar electrocoagulation was performed immediately on completion of the procedure. With piecemeal resection, all the pieces of the lesion were collected with net-type forceps. Conscious sedation was achieved by intravenous injection of midazolam (2 mg) before insertion of the colonoscope. A further 2 mg was also given repeatedly in some cases according to the decision of the endoscopist. Cardiopulmonary function was monitored. Carbon dioxide (CO₂) infusion was used instead of air infusion.

ESD/hybrid ESD procedures

Both ESD and hybrid ESD (HESD) were performed by two endoscopists (T.G, M.F). The same type of scope was used in both types of procedure. Before commencing resection, saline solution containing a small amount of indigo carmine was injected into the submucosa near the tumor through needle forceps. Indigo carmine is added to submucosal injection fluid in order to achieve a more clearly identifiable blue-colored submucosal layer. A monopolar knife is the most common choice at this institute (Dual Knife, IT knife-2, Olympus Medical Systems). The Dual Knife was used under the following settings : 30 W, effect 3, End-cut mode, and 30 W, effect 3, Forced coagulation mode with ICC200. Carbon dioxide was used instead of air infusion. Midazolam was administered intravenously for sedation as in the EMR/EMPR procedure. During ESD, a hard-type snare (20-mm spiral snare, Olympus Medical Systems) or a Captivator II Snare (Boston Scientific Co., MA, USA) was used if deemed necessary.

LECS procedure

The LECS procedure was performed under general anesthesia by a surgeon. A trocar was initially inserted at a site 12 mm to the left-lower abdominal site from the

middle/navel, followed by insertion of four more trocars. The affected mucosal and submucosal layers around the tumor were circumferentially dissected by using the ESD technique under intraluminal endoscopy. The lesion-sited liminal wall was then artificially perforated. The tumor identified under laparoscopy was intra-abdominally inversed, and seromuscular dissection performed. The whole lesion was dissected circumferentially by using an ultrasonically activated device along the demarcation line. The perforated portion of the duodenum was closed by automatic machine anastomosis.

Statistical analysis

Statistical analyses were performed with SPSS Statistics 22 (IBM Co. Ltd, Tokyo, Japan). Normally distributed data are presented as the mean \pm standard deviation. The Student *t*-test was used to determine significance; a *P*-value of < 0.05 was considered to indicate a statistically significant difference. Univariate analysis was performed for each potential risk factor using the chi-square test. In the second step, only significant factors on the chi-square analysis were included in a multivariate (logistic regression) analysis.

Results

Patient characteristics and clinicopathologic features of lesions

The mean age of the patients was 58.8 years. There were more men ($n = 32$) than women ($n = 15$). The mean tumor diameter was $13.4 \text{ mm} \pm 7.5 \text{ mm}$. Lesions were localized in the bulb in 3 cases (6.4%), the second portion in 42 (89.4%) (proximal side of the papilla, 17; distal side of the papilla, 25), and the third portion in 2 (4.2%). According to macroscopic type, 9 cases (19.1%) were type 0-I, 22 (46.8%) were type 0-IIa, 11 (23.4%) were type IIa + IIc, and 5 (10.6%) were type IIc. There were 25 reddish lesions (53%) and 15 were accompanied by erosion. Hemorrhage and white villi were observed in 1 (2.1%) and 33 (70%) lesions, respectively. Preoperative biopsy was carried out on 36 of a total of 47 duodenal lesions prior to primary endoscopic or surgical treatment. There were 39 cases (83%) of adenoma and 8 cases (17%) of adenocarcinoma (Table 1). On endoscopy, adenocarcinomas were either predominantly red or had patches of red significantly more often than did adenomas ($P < 0.05$). Erosion was seen significantly more frequently with adenocarcinoma than with adenoma ($P < 0.05$) (Table 2).

When the cancer-bearing rates were investigated according to tumor diameter and macroscopic type, 2 of 5 patients (40%) with type 0-I lesions and a tumor diameter of $\geq 15 \text{ mm}$ had cancer, whereas in cases with type 0-IIa + IIc lesions, 2 (33%) had cancer, even when the tumor diameter was $\leq 15 \text{ mm}$. Thus, the cancer-bearing rate was higher when the tumor diameter was larger. In

Table 1 Clinicopathological features

	Total ($n = 47$)
Mean age (mean \pm SD year)	58.8 (± 19.8)
Sex (M/F)	32/15
Tumor size (mean \pm SD mm)	13.4 (± 7.5)
Location	
bulbs	3 (6.4%)
2nd	42 (85.1%)
3rd	2 (4.3%)
Macroscopic type	
I	9 (19.1%)
IIa	22 (46.8%)
IIa + IIc	11 (23.4%)
IIc	5 (10.6%)
Endoscopic findings	
Redness	25 (53%)
Erosion	15 (31.9%)
Hemorrhage	1 (2.1%)
Whitened villi	33 (70%)
Preoperative biopsy	36 (76.6%)
Final histology	
Tubular adenoma	34 (72.4%)
Tubulovillous adenoma	5 (10.6%)
adenocarcinoma	8 (17%)

addition, no cancer was observed in type 0-IIa or type 0-IIc lesions (Table 3).

Outcome of endoscopic procedures

The following therapeutic methods were used to treat the lesions: hot biopsy, 1 case (2.2%); EMR, 32 (67%); EPMR, 9 (19%); HESD, 3 (4.4%); ESD, 1 (2.2%); and LECS, 1 (2.2%). Tumors of macroscopic types 0-I and 0-IIc could be resected en bloc with the usual snare; therefore, all were resected by EMR. However, flat tumors (type 0-IIa and 0-IIa + IIc) were treated with EPMR, HESD, or ESD, depending on the diameter of the tumor. Complete en bloc resection rates were 68.8% for EMR and 100% for HESD, ESD, and LECS. The mean procedure time was 15, 120, and 290 minutes for EMR, ESD, and LECS, respectively. The duration of hospitalization after ESD or LECS was longer than that after EMR. Regarding adverse events, delayed bleeding was observed in 3 cases. Clip suture was performed in 39 patients (87%); however, of those, 2 who experienced delayed bleeding had not received clip suturing. No perforation was observed during or after the procedure. Four patients underwent the procedure under general anesthesia, and a pancreatic stent was placed preoperatively in 2 patients because the tumor and papilla were close to each other (Table 4).

Regarding the relationship between CR rate and tumor size/macroscopic type, the CR rate with elevated lesions such as type IIa or I when smaller than 15 mm was high,

Table 2 Relationship between endoscopic findings and final histological diagnosis

	Adenoma (n = 39)	Adenocarcinoma (n = 8)	P-value
Tumor size (mean ± SD mm)	12.6 (± 7.7)	16.6 (± 5.7)	N.S
Location			
bulbs	3 (7.7%)	0	N.S
2nd	34 (8.7%)	8 (100%)	N.S
3rd	2 (5.1%)	0	N.S
Macroscopic type			
I	7 (14.9%)	2 (4.3%)	N.S
IIa	22 (46.8%)	0 (0%)	N.S
IIa + IIc	5 (10.6%)	6 (12.8%)	N.S
IIc	5 (10.6%)	0 (0%)	N.S
Endoscopic findings			
Redness	17 (43.6%)	7 (87.5%)	<i>P</i> < 0.05
Erosion	7 (18%)	6 (75%)	<i>P</i> < 0.05
Hemorrhage	—	1 (12.5%)	N.S
Whitened villi	18 (46.2%)	3 (37.5%)	N.S

Table 3 Rate of carcinoma according to duodenal tumor macroscopic type

Macroscopic type	≤ 15 mm	> 15 mm
0-I (n = 9)	0% (0/4)	40% (2/5)
0-IIa (n = 22)	0% (0/12)	0% (0/10)
0-IIa+IIc (n = 11)	33% (2/6)	80% (4/5)
0-IIc (n = 5)	0% (0/5)	(—)
Total	2 (7.4%)	6 (30%)

Table 4 Short term of clinical outcome and results in resected specimens

	Hot (n = 1)	EMR		ESD		LECS (n = 1)
		EMR (n = 32)	EPMR (n = 9)	HESD (n = 3)	ESD (n = 1)	
Macroscopic type						
I	0	9	0	0	0	0
IIa	1	12	7	0	0	1
IIa+IIc	0	6	2	3	1	0
IIc	0	5	0	0	0	0
Tumor size (mean : mm)	3	10.9	19.4	17.5	20	25
Complete resection rate	—	68.8% (22/32)	—	100% (3/3)	100% (1/1)	100% (1/1)
Procedure time (mean : min)	8	15	36	48	120	290
Hospitalization (days)	3	5.3	6.6	7.2	15	16
Complications						
Delayed bleeding	0	0	2 (22%)	1 (33%)	0	0
Perforation	0	0	0	0	0	0
Histology						
adenoma/M/SM	1	28/4/0	8/1/0	1/2/0	0/0/1	1/0/0
lymphovascular invasion		—		—	—	

but with type IIa + IIc or type IIc lesions it was approximately 40%.

With a tumor diameter of more than 15 mm, the CR

rate with type I lesions was high ; EPMR was performed for many type IIa lesions, whereas HESD or ESD was sometimes performed for IIa + IIc lesions (Table 5).

Table 5 Relationship between CR rate and tumor size /macroscopic type

	≤ 15 mm			> 15 mm				
	hot (n = 1)	EMR		EMR		ESD		LECS (n = 1)
		EMR (n = 25)	EPMR (n = 1)	EMR (n = 7)	EPMR (n = 8)	HESD (n = 3)	ESD (n = 1)	
I	—	4 (CR : 100%)	—	5 (CR : 100%)	—	—	—	—
IIa	1 (CR : 0%)	11 (CR : 82%)	—	1 (CR : 0%)	7 (CR : 0%)	1 (CR : 100%)	—	1 (CR : 100%)
IIa + IIc	—	5 (CR : 40%)	1 (CR : 0%)	1 (CR : 0%)	1 (CR : 0%)	2 (CR : 100%)	1 (CR : 100%)	—
IIc	—	5 (CR : 40%)	—	—	—	—	—	—
CR rate	0%	68% (17/25)	0%	71% (5/7)	0%	100% (3/3)	100% (1/1)	100% (1/1)

CR : complete resection

Case report

A 75-year-old man presented with a 1-week history of epigastralgia. Endoscopy revealed a 20-mm type IIa + IIc lesion in the second portion, opposite to the papilla. Because the lesion was large and included a depression, ESD was performed. The lesion was completely removed en block.

The size of the resected tumor was 15 × 14 mm, and histopathologic examination revealed well differentiated tubular adenocarcinoma with submucosal (SM) invasion of 300 μm (Figure 1, 2).

Follow-up outcome

The mean follow-up period was 24.3 months. Residual/local recurrence was observed in 2 patients. One of these patients had a 3-mm type IIa lesion in the second portion of the duodenum and was first treated by hot biopsy. A 2-mm residual lesion observed on examination 6 months after this procedure was also treated with hot biopsy. Histopathological examination revealed that the lesion was an adenoma. The other patient had a 15-mm type IIa + IIc lesion in the second portion of the duodenum, and hot biopsy was additionally performed for a minimal residual lesion after EMR. Histopathological examination revealed that the lesion was an intramucosal adenocarcinoma. Because the resection margin was unclear, however, reexamination was performed 3 months later. A 5-mm-diameter elevated lesion was observed at the scar of the procedure ; therefore, hot biopsy was performed. Histopathological examination revealed that the tumor was an adenocarcinoma. No residual tumor or recurrence has been observed on follow-up endoscopy in either of the lesions (Table 6).

Discussion

Cases of primary non-ampullary duodenal tumors are rare, and fewer have been reported than those of esophageal, gastric, or colonic tumors. Therefore, the clinicopathological features of this type of tumor and the standard therapeutic approach remain to be established. In this study, we investigated clinicopathological features and endoscopic treatment outcomes in primary non-ampullary duodenal tumors. Endoscopic findings revealed that adenocarcinoma was more likely to present with redness than adenoma. When cancer-bearing rates were compared according to macroscopic type or tumor diameter, the cancer-bearing rate of type 0-IIa lesions tended to be low and that of type 0-IIa + IIc or 0-I with a tumor diameter of ≥15 mm tended to be high. In addition, the cancer-bearing rate increased with increase in tumor diameter.

Endoscopy is indicated for neoplastic lesions with no potential lymph node metastasis. In a study of 128 patients with early duodenal cancer, Nagatani et al. reported that lymph node metastasis was not observed in patients with mucosal (M)-cancer, but that lymph node metastasis was observed in ≥ 5% of the patients with SM-cancer²⁾. In a study of 396 patients, Goda et al. reported that lesions with a tumor diameter of ≥ 6 mm and redness on the surface were very likely to be high-grade adenoma/adenocarcinoma ; all cases of SM-invasive carcinoma presented with redness ; and the macroscopic type was either 0-I or 0-IIa + IIc¹⁶⁾. Kakushima et al. reported that 11 of 13 lesions diagnosed as high-grade adenoma by biopsy were finally revealed to be adenocarcinoma according to histopathological examination of the resected specimen²⁰⁾. These findings suggest that if an untreated tumor is ≥ 5 mm in diameter and is

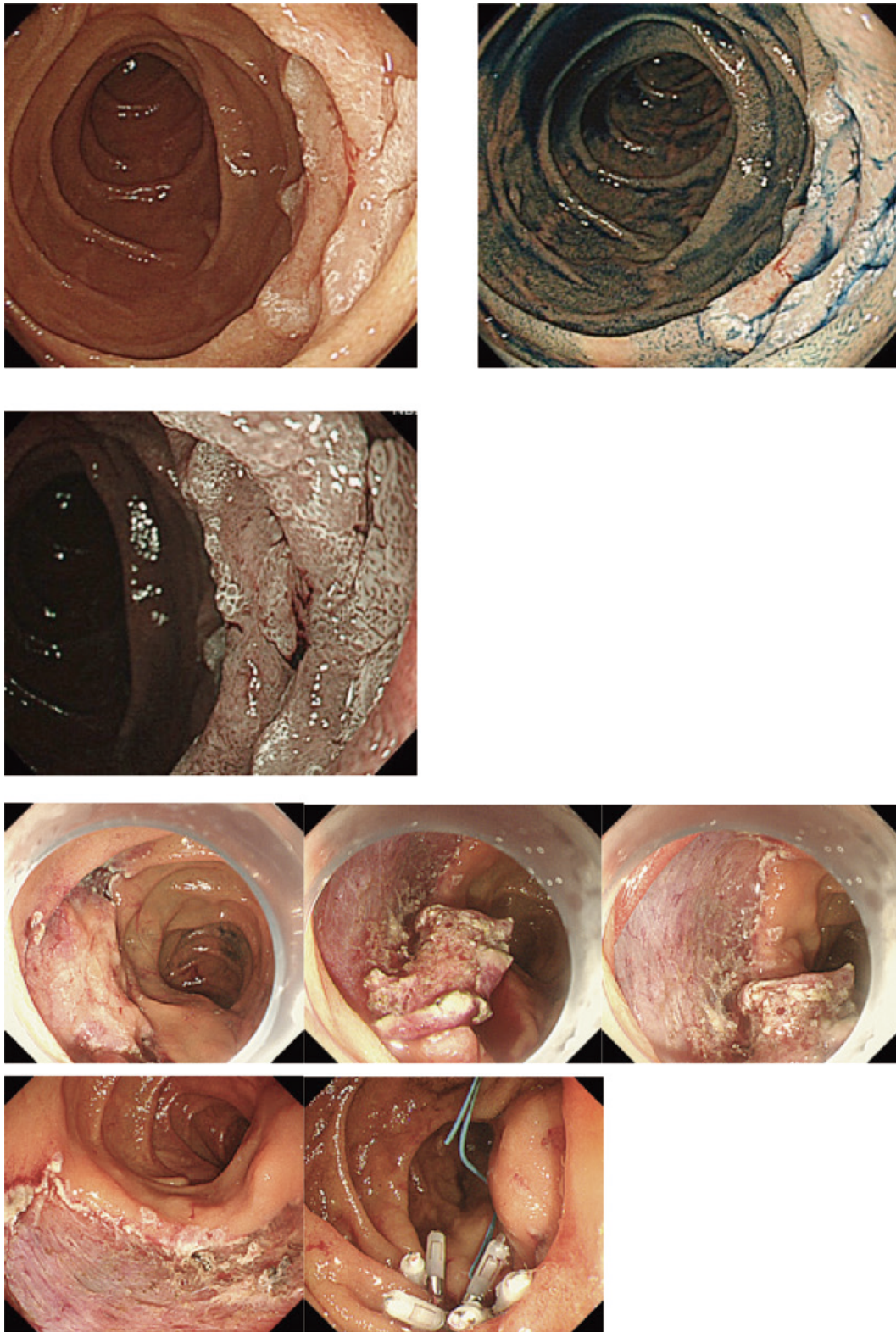


Fig. 1 Endoscopic view of duodenal tumor
Male patient aged 75 yr ; 2nd portion (opposite papilla), 20 mm, 0-IIa + IIc

histologically diagnosed as high-grade adenoma, it can be treated. The present results also suggest that the cancer-bearing rates of types 0-IIa + IIc and 0-I tumors are high, so this type of tumor may be SM-invasive and

should be resected en bloc.

Preoperative biopsy was carried out in 36 of a total 47 duodenal lesions prior to primary treatment at our hospital. Only one original diagnosis of low-grade adenoma

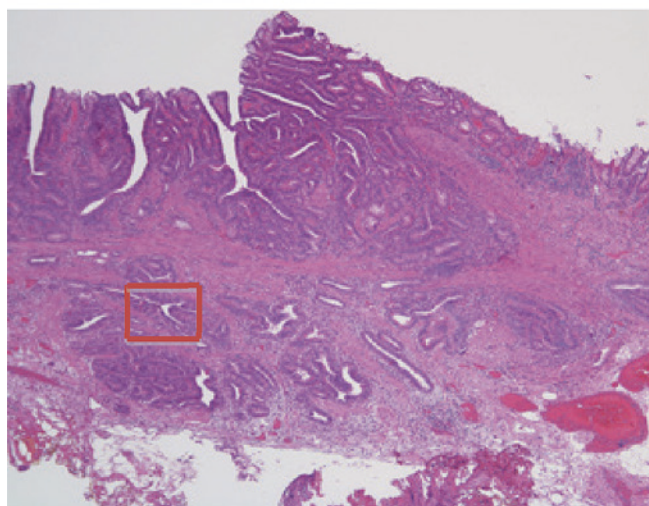
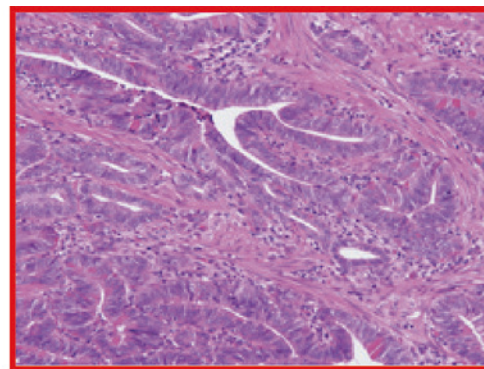



Fig. 2 Pathological diagnosis
Well-differentiated tubular adenocarcinoma (tub1)
(15 × 14 mm, 0-IIa + IIc, pSM (300 μm), v0, ly0, HM0,
VMO)

Table 6 Residual/Recurrent lesions

	EMR (<i>n</i> = 1)	Hot (<i>n</i> = 1)
Macroscopic type	IIa + IIc	IIa
Tumor size prior to treatment (mm)	15	3
Tumor size of residual/recurrent lesion (mm)	5	2
Additional treatment	Hot biopsy	Hot biopsy
Time of additional treatment	1	1
Histology	adenocarcinoma	adenoma

based on a preoperative biopsy was changed to carcinoma according to a final histological analysis. The accuracy of preoperative diagnosis by biopsy for adenoma or carcinoma was 94%. Preoperative biopsy is very useful in achieving a definitive diagnosis. However, actually, the lesion was accompanied by severe fibrosis in the submucosal layer and did not show large elevation, even with glycerin injection, probably due to many biopsies prior to treatment. We tried EMR for one IIa + IIc 10-mm lesion accompanied by severe fibrosis according to the results of several biopsies. There was no sign of elevation, however, and finally the lesion

was treated by EPMR. When endoscopic resection is being considered for a lesion, especially if it is flat or depressed, it is necessary to assess the degree of neoplastic atypism by endoscopic means rather than relying on a biopsy, as a biopsy may cause fibrosis. Thus, preoperative biopsy should be avoided.

Standard strategies for the endoscopic treatment of duodenal tumors remain to be established. Handling the endoscope is often difficult due to the anatomical characteristics of the duodenum, such as the thin wall and narrow lumen. Therefore, the incidence rate of adverse events during and after the procedure is higher in

the duodenum than in other digestive tracts ; thus, extra caution should be exercised when selecting a treatment method. In the present study, the mean tumor diameter in which EMR was performed was 10.9 mm.

When performed on type I or type IIa lesions smaller than 15 mm, EMR yielded a high CR rate, but when applied in type IIa + IIc or type IIc lesions the CR rate was low. This suggests that 10–15-mm elevated lesions can be resected completely by EMR. On the other hand, in the case of 10–15-mm recessed lesions suspected as cancer by preoperative endoscopy, ESD or HESD should be considered, although the latter offers the best option as it requires less time to perform than the former. The mean diameter of the tumors in which EPMR, ESD, HESD, or LECS was performed was large (≥ 15 mm). Most (77.8%) of the lesions in which EPMR was performed were type IIa, and no local recurrence was observed during the follow-up observation. Regarding HESD and ESD, en bloc resection is possible, even in large tumors. At our hospital, 75% of tumors in which HESD or ESD was performed were type IIa + IIc. Histopathologically, the cancer-bearing rate of type IIa lesions is low, whereas that of type IIa + IIc lesions is high. Therefore, EPMR should be considered for type IIa lesions of 15 mm, whereas en bloc resection such as HESD or ESD should be considered for type IIa + IIc lesions. However, in the case of HESD and ESD, the procedure time and duration of hospitalization tended to be long, although the rate of en bloc resection was high. Although no differences were observed in adverse events at our hospital, this may have been because the number of cases was small. Honda et al. reported that delayed perforation occurred in 2 (22%) of 9 patients who underwent ESD for a duodenal tumor⁹⁾. Takahashi et al.¹⁰⁾, Endo et al.¹²⁾, and Jung et al.¹³⁾, reported intraoperative perforation in 50% (2/4), 20% (1/5), and 35.7% (5/14) of patients, respectively. Furthermore, Inoue et al.²¹⁾ endoscopically resected duodenal tumors in 63 patients and reported postoperative delayed perforation in 6.3%. In all of these cases, EPMR or ESD had been performed on the distal side of the papilla, indicating that delayed perforation was associated with tumor site or resection method. As for measures against postoperative adverse events, many studies have reported that clip suture is effective in the treatment of postoperative ulcers¹⁷⁾²²⁾. In the present study, 3 patients (66%) had secondary hemorrhage as an adverse event, of whom 2 had not received clip suturing. Recent studies have shown that endoscopic ulcers can be prevented by shielding of mucosal defects with polyglycolic acid sheets and fibrin glue^{23–25)}, and suturing is performed using an Over-The-Scope Clip system²⁶⁾. These procedures are expected to be widely used in the future.

In the present study, the patient in whom LECS was

performed had a 25-mm type IIa lesion in the superior duodenal angle. We chose LECS here as handling the endoscope was difficult and the lesion was on the opposite side of the papilla (Fig. 1–2). This procedure is less invasive than laparoscopic surgery alone and it also allows firmer suturing of the resected surface than endoscopic resection. Thus, it has merit in reducing the risk of postoperative complications. However, the sites at which it can be applied are limited : it cannot be applied when the lesion is on the duodenal papilla side or when the size of the lesion is larger than one-third of the circumference of the duodenum. It also carries the risk of intraperitoneal exposure, a problem that needs to be addressed²⁷⁾.

Regarding residual and recurrent lesions, small, possibly residual lesions were observed in patients who underwent hot biopsy and EMR. Additional endoscopic treatment was performed in all of these patients. To date, no recurrence has been observed, and the patients are still being followed. Only a few studies have focused on long-term results after endoscopic treatment. Nonaka et al. reported long-term outcomes in 121 patients with duodenal tumor treated with endoscopic surgery (en bloc resection, 77 patients ; piecemeal resection, 43 patients) and found that none had local failure such as recurrence of invasive cancer, suggesting that EMR, including piecemeal resection, can be indicated for duodenal tumors¹⁷⁾.

The aforementioned findings suggest that endoscopic treatment of primary non-ampullary duodenal tumors is much more effective than surgical resection. Although further study is needed to establish standard therapeutic methods for duodenal tumors, we believe that not all lesions need to be resected en bloc ; instead, piecemeal resection of lesions, if clinicopathologically possible, may be required to prevent the occurrence of adverse events.

The present study had several limitations. It was performed at a single center by 2 skilled endoscopists with a relatively small number of patients, and there was no control group.

In conclusion, the treatment outcomes described here suggest that while en bloc resection is preferable in type 0–I or IIa + IIc lesions in the case of non-ampullary duodenal tumors, piecemeal resection can be indicated in type IIa lesions. Selection of ESD, HESD, or surgical resection should depend on tumor diameter, lesion site, or maneuverability of the endoscope. Whether a lesion is cancerous and whether resection can be performed safely should be considered in selecting the therapeutic approach.

References

- 1) Spira IA, Ghazi A, Wolff WI : Primary adenocarci-

- noma of the duodenum. *Cancer* **39** : 1721-1726, 1977
- 2) Nagatani K, Takekoshi T, Baba Y, Kaku Y, Koizumi K, Fujii A, Ogata E, Yanagisawa A : Indications for endoscopic treatment of early duodenal cancer : based on cases reported in the literature (in Japanese with English abstract). *Endosc Dig* **7** : 969-976, 1993
 - 3) Haubrich WS, Johnson RB, Foroozan P : Endoscopic removal of a duodenal adenoma. *Gastrointestinal Endoscopy* **19** : 201, 1973
 - 4) Tanigawa K, Akino K, Kajiwara Y, Ozeki K, Kanematsu T, Shibata H, Yamashita S : A small depressed early cancer of the second portion of duodenum. *Chinese Medical Journal* **109** : 810-813, 1996
 - 5) Hirasawa R, Ishii H, Tatsuta M, Ishiguro S : Clinicopathologic feature and endoscopic resection of duodenal adenocarcinoma and adenomas with the submucosal saline injection technique. *Gastrointestinal endoscopy* **46** : 507-512, 1997
 - 6) Kume K, Okubo Y, Ejiri Y, Abe S, Hakozaki H, Murata I, Yoshikawa I, Otsuki M : Early duodenal carcinoma successfully treated by endoscopic mucosal resection. *Digestive endoscopy* **12** : 177-180, 2000
 - 7) Ahmad NA, Kochman ML, Long WB, Furh EE, Ginsberg GG : Efficacy, safety, and clinical outcome of endoscopic mucosal resection : a study of 101 cases. *Gastrointestinal endoscopy* **55** : 390-396, 2002
 - 8) Sanomura M, Tanaka S, Ito M, Chayama K : Depressed-type, early duodenal carcinoma (carcinoma in situ) treated by endoscopic mucosal resection. *Journal of Gastroenterology* **38** : 813-815, 2003
 - 9) Honda T, Yamamoto H, Osawa H, Yoshizawa M, Nakano H, Sunada K, Hanatsuka K, Sugano K : Endoscopic submucosal dissection for superficial duodenal neoplasms. *Digestive Endoscopy* **21** : 270-274, 2009
 - 10) Takahashi T, Ando T, Kabeshima Y, Kawakuo H, Shito M, Sugiura H, Omori T : Borderline cases between benignancy and malignancy of duodenum diagnosed successfully by endoscopic submucosal dissection. *Scandinavian Journal of Gastroenterology* **44** : 1377-1383, 2009
 - 11) Shinoda M, Makino A, Wada M, Kabeshima Y, Takahashi T, Kawakubo H, Shito M, Sugiura H, Omori T : Successful endoscopic submucosal dissection for mucosal cancer of the duodenum. *Digestive Endoscopy* **22** : 49-52, 2010
 - 12) Endo M, Abiko Y, Oana S, Kudara N, Chiba T, Suzuki K, Koizuka H, Uesugi N, Sugai T : Usefulness of endoscopic treatment for duodenal adenoma. *Digestive Endoscopy* **22** : 360-365, 2010
 - 13) Sohn JW, Jeon SW, Cho CM, Jung MK, Kim SK, Lee DS, Son HS, Chung IK. Endoscopic resection of duodenal neoplasms : a single-center study. *Surg Endosc* **24** : 3195-3200, 2010
 - 14) Matsumoto S, Miyatani H, Yoshida Y : Endoscopic submucosal dissection for duodenal tumors ; a single center experience. *Endoscopy* **45** : 136-137, 2013
 - 15) Navaneethan U, Lourdasamy D, Mehta D, Lourdasamy V, Venkatesh PG, Sanaka MR : Endoscopic resection of large sporadic non-ampullary duodenal polyps : efficacy and long-term recurrence. *Surg Endosc* **28** : 2616-2622, 2014
 - 16) Goda K, Kikuchi D, Yamamoto Y, Takimoto Y, Kakushima N, Morita Y, Doyama, Gotoda T, Maehata Y, Abe N : Endoscopic diagnosis of superficial non-ampullary duodenal epithelial tumors in Japan : Multicenter case series. *Digestive Endoscopy* **26** : 23-29, 2014
 - 17) Nonaka S, Oda I, Tada K, Mori G, Sato Y, Abe S, Suzuki H, Yoshinaga S, Nakajima T, Matsuda T, Taniguchi H, Saito Y, Maetani I : Clinical outcome of endoscopic resection for nonampullary duodenal tumors. *Endoscopy* **47** : 129-135, 2015
 - 18) Yamamoto Y, Yoshizaki N, Tomida H, Fujisaki J, Igarashi M : Therapeutic outcome of endoscopic resection for superficial non-ampullary duodenal tumors. *DigestiveEndoscopy* **26** : 50-56, 2014
 - 19) Japanese Society for Cancer of the Colon and Rectum. Japanese classification of colorectal carcinoma 8th ed 9-10, Kanehara Shuppan (Tokyo), 2013
 - 20) Kakushima N, Ono H, Takao T, Knemoto H, Saeki K : Method and timing of resection of superficial non-ampullary duodenal epithelial tumors. *Digestive Endoscopy* **26** : 35-40, 2014
 - 21) Inoue T, Uedo N, Yamashina T, Yamamoto S, Hanaka N, Takeuchi Y, Higashino K, Ishihara R, Ishii H, Tatsuta M, Eguchi H, Ohigashi H : Delayed perforation : A hazardous complication of endoscopic resection for non-ampullary duodenal neoplasm. *Digestive endoscopy* **26** : 220-227, 2014
 - 22) Matsumoto S, Yoshida Y. Selection of appropriate endoscopic therapies for duodenal tumors : An open-label study, single-center experience : *World Journal of Gastroenterology* **20** : 8624-8629, 2014
 - 23) Takimoto K, Toyonaga T, Matsuyama K : Endoscopic tissue shielding to prevent delayed perforation associated with endoscopic submucosal dissection for duodenal neoplasms. *Endoscopy* **44** : 414-415, 2012
 - 24) Doyama H, Tominaga K, Yoshida N, Takemura K, Yamada S : Endoscopic tissue shielding with polyglycolic acid sheets, fibrin glue and clip to prevent delayed perforation after duodenal endoscopic resection. *DigestiveEndoscopy* **26** : 41-45, 2014
 - 25) Takimoto K, Imai Y, Matsuyama K : Endoscopic tissue shielding method with polyglycolic acid sheets and fibrin glue to prevent delayed perforation after duodenal endoscopic submucosal dissection. *Digestive Endoscopy* **26** : 46-49, 2014
 - 26) Mori H, Fujihara S, Kobara H, Nishiyama N, Kazi Rafiq, Kobayashi M, Nakatsu T, Michi N, Suzuki Y,

Masaki T : Successful closing of duodenal ulcer after endoscopic submucosal dissection with over-the-scope clip to prevent delayed perforation. Digestive endoscopy **25** : 459-461, 2013

27) Ohata K, Murakami M, Yamazaki K, Nonaka K, Mi

sumi N, Tashima T, Minato Y, Shouzushima M, Mitsui T, Matsuhashi N, Kuangi Fu : Feasibility of endoscopy-assisted laparoscopic full-thickness resection for superficial duodenal neoplasms. The Scientific World Journal Article ID239627, 6 page, 2014

非乳頭部十二指腸腫瘍に対する内視鏡治療成績

竹 内 眞 美 福 澤 誠 克 河 合 隆
森 安 史 典

東京医科大学消化器内科

【要旨】 背景：非乳頭部原発性十二指腸腫瘍はまれな病変疾患である。そのため十分な症例集積がなされておらずその内視鏡像の特徴・深達度診断・治療法は確立されていない。今回我々は当院で経験した非乳頭部原発性十二指腸腫瘍 47 例の臨床病理学的特徴およびその内視鏡治療成績について検討した。

方法：内視鏡切除が施行された十二指腸腫瘍 47 例を対象とし、年齢・性別・腫瘍径・占居部位・色調・肉眼型・組織型・（肉眼型 / ）腫瘍径別の担癌率などの臨床病理学的特徴および治療法別の腫瘍径・占居部位・肉眼型・短期治療成績（組織型・深達度・脈管浸襲・一括切除率・偶発症）について検討した。さらに、6 ヶ月以上経過観察が可能だった 30 病変を対象として遺残再発率を検討した。

結果：内視鏡所見では腺腫と腺癌を比較した場合、発赤・びらんを認めるものが有意に癌で多かった ($P < 0.05$)。肉眼型と腫瘍径による担癌率の比較では、0-IIa+IIc 型において 15 mm 未満：33%，15 mm 以上：80%，0-I 型 15 mm 以上：40% の担癌率を認めた。一方 0-IIa 型、0-IIc の担癌率は 0% であった。治療法別の平均腫瘍径をみると EMR は 10.9 mm、EPMR、ESD、Hybrid ESD (HESD)、LECS を行った腫瘍の平均腫瘍型は全て 15 mm 以上と大きかった。一括切除率は EMR では 68.8%、HESD、ESD、LECS では 100% であった。

結論：0-IIa 型の担癌率は低く、0-IIa+IIc 型、15 mm 以上の 0-I 型において担癌率が高い傾向がみられた。10-15 mm の隆起性病変に関しては EMR で対応可能と考えられるが、癌を疑う陥凹を伴う病変は ESD もしくは ESD より短時間での処置が可能な HESD を検討すべきである。15 mm 以上の IIa 病変は EPMR、IIa+IIc 病変は一括切除をめざすべき病変と考えられた。その病変の肉眼型、担癌率および技術的な安全性を十分考慮し治療法を選択していくことが重要である。

〈キーワード〉十二指腸腫瘍、内視鏡切除、治療成績
